



Content available at: <https://www.ipinnovative.com/open-access-journals>

Journal of Oral Medicine, Oral Surgery, Oral Pathology and Oral Radiology

Journal homepage: [www.joooo.org](http://www.joooo.org)



## Original Research Article

# Topographic study of antral teeth on computed tomography in a beninese population

Sylvie Arlette Bancole Pognon<sup>1,\*</sup>, Mamadou Diatta<sup>2</sup>, Mamadou Lamine Ndiaye<sup>2</sup>,  
Mohamed Djivede Akanni<sup>3</sup>, Babacar Tamba<sup>2</sup>, Francois Avakoudjo<sup>4</sup>,  
Patricia Yekpe Ahouansou<sup>5</sup>, Soukeye Dia Tine<sup>2</sup>, Wassi Adjibabi<sup>4</sup>

<sup>1</sup>University Clinic for Odontostomatology and Maxillofacial Surgery at the HKM University Hospital Centre (CNHU HKM) in Cotonou - Faculty of Health Sciences (FHS), University of Abomey Calavi (UAC), Benin

<sup>2</sup>Dept. of Oral Surgery, Odontology and Stomatology Institute, Cheikh Anta Diop University, Dakar, Senegal

<sup>3</sup>Dept. of Medical Imagine, Centre Hospitalier Universitaire Départemental du Borgou, Parakou, Benin

<sup>4</sup>Training and Research Unit of ENT and Cervico-facial Surgery FHS/UAC, Benin

<sup>5</sup>Training and Research Unit of Medical Imaging and Radiodiagnostics FHS/UAC, Benin



## ARTICLE INFO

### Article history:

Received 27-06-2023

Accepted 07-08-2023

Available online xx xx xxxx

### Keywords:

Root tips

Maxillary sinus

Topographical relationships

Facial CT

Sinus mucosal thickening

## ABSTRACT

**Background:** The topographical relationships between the root tips and the floor of the maxillary sinus favour the occurrence of odontogenic maxillary sinus pathologies. Knowledge of these relationships may help to prevent such pathologies. The aim of this study was to investigate the anatomical relationships between the maxillary sinuses and the apices of the maxillary roots in a Beninese population using computed tomography (CT) images of the maxilla.

**Materials and Methods:** This was a descriptive study of CT scans of facial masses performed between January 2020 and January 2023 in subjects aged at least 18 years without tumour or traumatic sinus pathology. The CT images were in Dicom format. Horos, Excel and SPSS software were used for data collection, entry and analysis.

**Results:** Of the 346 CT scans collected, 255 were included in the analysis. The mean age of the subjects was  $42.65 \pm 16.57$  years and the sex ratio was 2. More than half of the cases involved 3rd molars within the sinus. In 99% of cases, the sinus alveolar recess was located in the root furcation zone. The mean volume of the right sinus was  $13.78 \pm 4.59$  ml and that of the left sinus was  $13.65 \pm 4.75$  ml. Anterior sinus extensions were located in the premolar region (75%) and posterior sinus extensions were located in the tuberosity region (88 to 90%). In 3 out of 4 subjects the sinus floor had an irregular shape.

**Conclusion:** These various insights into the relationships between the maxillary root apices and the sinus floor will be of considerable help to dental surgeons in the prevention of odontogenic maxillary sinus pathology.

This is an Open Access (OA) journal, and articles are distributed under the terms of the [Creative Commons Attribution-NonCommercial-ShareAlike 4.0 License](https://creativecommons.org/licenses/by-nc-sa/4.0/), which allows others to remix, tweak, and build upon the work non-commercially, as long as appropriate credit is given and the new creations are licensed under the identical terms.

For reprints contact: [reprint@ipinnovative.com](mailto:reprint@ipinnovative.com)

## 1. Introduction

Pathologies of the maxillary sinus can be of infectious, tumour or iatrogenic origin. The most common is maxillary sinusitis, an inflammatory disease of the sinus mucosa that

may or may not be of rhinological origin.<sup>1,2</sup> Odontogenic maxillary sinusitis is non-rhinological and quite common. Coulibaly in Mali reported an annual hospital prevalence of 55 cases in 2014.<sup>3</sup> In 2008, Broome in Switzerland found a dental origin in 10% of all cases of maxillary sinusitis and in 40% of chronic maxillary sinusitis.<sup>2</sup>

\* Corresponding author.

E-mail address: [pobasfr@yahoo.fr](mailto:pobasfr@yahoo.fr) (S. A. B. Pognon).

The anatomical proximity of the maxillary root tips to the maxillary sinus provides a pathway for the spread of dental infections, which explains this significant incidence.<sup>2</sup> The sinus teeth vary from author to author. While some authors identify the maxillary first molars as the most common intrasinus teeth,<sup>2,4</sup> others identify the second molars as the most common proximal teeth.<sup>5–19</sup> In Benin, no study had investigated the topographical relationship between the root apices and the floor of the maxillary sinus. Dental surgeons' knowledge of these anatomical relationships would help prevent odontogenic maxillary sinusitis. This research project was initiated to gain a better understanding of the antral teeth in a Beninese population. The aim was to describe the anatomical relationships between the maxillary sinuses and the maxillary root apices in a Beninese population using computed tomography (CT) images of the maxilla.

## 2. Materials and Methods

### 2.1. Type of study

This was a descriptive cross-sectional study of the anatomical relationships between the maxillary sinus floors and the maxillary root apices.

### 2.2. Study population

All computed tomography (CT) scans of the facial mass performed between January 2020 and January 2023 at the Medical Imaging Department of the CNHU HKM in Cotonou in Beninese subjects aged at least 18 years and meeting our inclusion criteria. The images were in Dicom format.

### 2.3. Inclusion criteria

CT scans of the facial mass centred on the maxilla in subjects aged at least 18 years and free of tumour and traumatic sinus pathology.

### 2.4. Non inclusion criteria

CT scans of subjects with edentulous maxilla. In addition, pneumosinus dilatans, blurred images (poor quality), images that did not show the entire sinus, and images with missing data (age and sex) were not included in this study.

### 2.5. Sample

This was an exhaustive recruitment of all CT scans of the facial mass performed between 1 January 2020 and 20 January 2023 that met our inclusion criteria. CT scans were performed without contrast injection. Bone window images were used for data collection.

### 2.6. Technique used to collect data from CT images

The 3D MPR (Multiplanar Reconstruction) option of the Horos 3.0 medical image viewing software was used to generate 3D reconstructions (sagittal, coronal and axial) of each subject's facial CT scans. The following data were then recorded according to the following procedures:

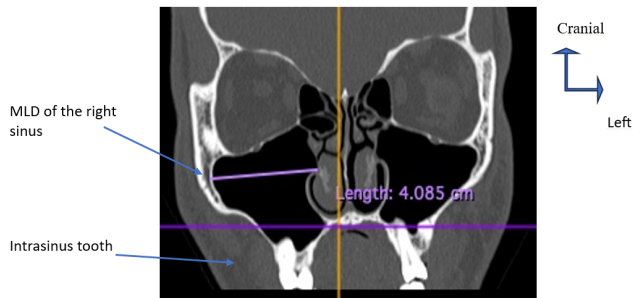
1. Vertical relationships most at risk to the maxillary sinus (root apices are intra-sinus and those in contact with or within 0.5 mm of the sinus floor) were identified based on inspection of the 3 CT sections of the facial mass (coronal, sagittal and axial).
2. Horizontal relationships are represented by the position of the sinus alveolar recess, the most inclined part of the sinus floor, in relation to the root apices.<sup>14</sup> They were assessed on a sagittal section.
3. Sinus volume was calculated from 3 sagittal, axial and coronal sections using the Horos software length measurement tool. The medio-lateral diameter (MLD) or width, measuring the greatest distance between the medial and lateral walls, was determined by comparing the dimensions obtained in 2 sections (axial and coronal) (Figures 1 and 3). The craniocaudal diameter (CCD) or height of the sinus was measured as the greatest distance between the superior and inferior walls of the sinus after comparing the dimensions obtained on the 3 sections (axial, sagittal and coronal) (Figure 2). The anteroposterior diameter (APD) or depth measured the greatest distance between the anterior and posterior walls after comparing the dimensions obtained on 2 sections (sagittal and axial) (Figures 2 and 3). Volume was calculated using the following formula  $MLD \times CCD \times APD \times \frac{1}{2}$ .<sup>20</sup>
4. The shape of the sinus floor was assessed on the sagittal sections.
5. The height of the anterior and posterior extensions was assessed on sagittal sections.
6. Sinus mucosal thickening was assessed on 3 CT sections.

### 2.7. Data entry and analysis

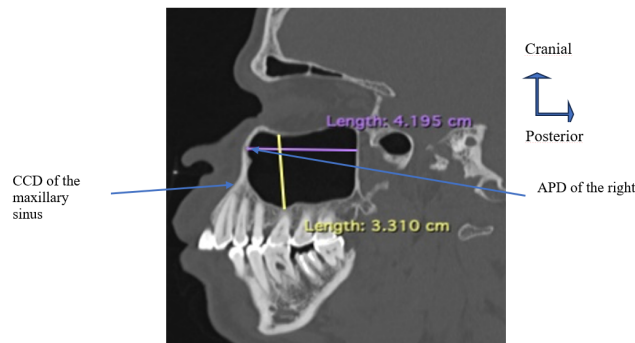
Data were entered using Excel 16.73, then processed and analysed using SPSS (Statistical Package of Social Sciences) version 20.0 Inc.

Standard descriptive statistics are used for the main variables studied. Means and standard deviations will be used to describe quantitative variables, while qualitative variables will be described by their frequencies and confidence intervals.

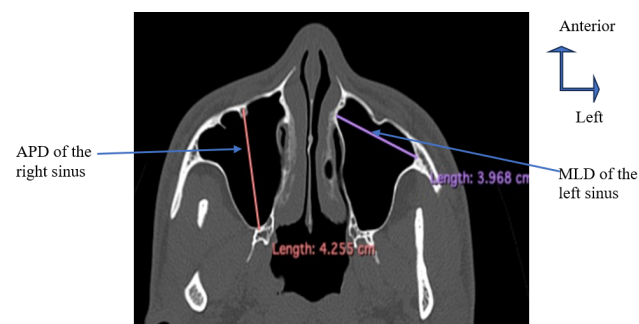The analytical study will use the chi-squared test of independence or the t-test to compare means. The significance level will be set at 0.05.



**Fig. 1:** Coronal reconstruction in the bone window of the CT scan of the facial mass showing the measurement of the medio-lateral diameter (MLD) of the right maxillary sinus



**Fig. 2:** Sagittal bone-window reconstruction of the CT scan of the facial mass showing measurement of the craniocaudal (CCD in yellow) and anteroposterior (APD in purple) diameters of the left maxillary sinus



**Fig. 3:** Bone-window axial reconstruction of the CT scan of the facial mass, showing measurement of the anteroposterior diameter (APD) of the right sinus and the mediolateral diameter (MLD) of the left sinus

### 3. Results

A total of 255 of the 346 collected facial scans met our inclusion criteria, i.e. 510 maxillary sinuses.

#### 3.1. Demographic aspects

The mean age of the subjects was  $42.65 \pm 16.57$  years, with extremes of 18 and 82 years. The sex ratio was 2.

#### 3.2. Anatomical characteristics

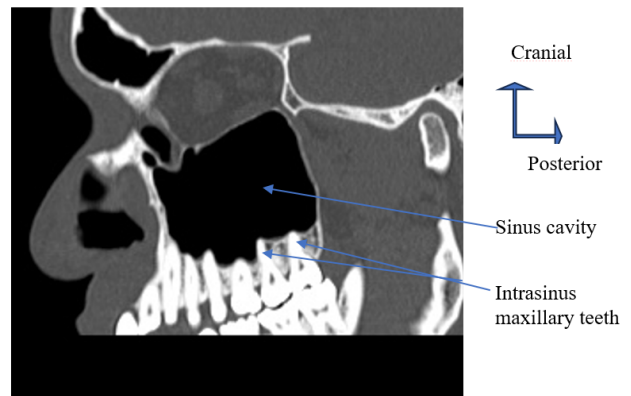
##### 3.2.1. Sinus volume

The mean volume of the right sinus was  $13.78 \pm 4.59$  ml, with extremes of 3 and 27 ml, and that of the left sinus was  $13.65 \pm 4.75$  ml, with extremes of 3 and 29 ml. There was no difference between right and left sinus volumes ( $p=0.2$ ) and sinus volume was not related to gender ( $p=0.13$ ).

##### 3.2.2. Relationship between root apices and sinus floor

Vertically, the distribution of subjects according to the frequency of intra-sinus teeth and teeth in contact with the sinus floor is shown in Tables 1 and 2 respectively.

On the right side, there were 29 cases (14.5%) of sinus intrusion of all teeth from 15 to 18, 1 case of intrusion of all teeth from 14 to 18 (Figure 4), and 1 case of intrusion from 13 to 18. On the left, there were 19 cases (10.05%) of intrasinus intrusion of teeth from 25 to 28.



**Fig. 4:** Showing sinus intrusion from canine to 3rd molar without sinus mucosal thickening

In terms of horizontal relationships, the sinus alveolar recess was in the intrafurcation region in 98.68% of cases.

#### 3.3. Sinus extensions

The distribution of subjects according to the level of anterior sinus extension is shown in Table 3.

With regard to posterior extensions, 90.48% of cases on the right and 88.14% on the left were in the tuberosity region.

**Table 1:** Distribution of subjects according to the frequency of intrasinus teeth

Teeth	Right size					Left size			
Number	15	16	17	18	25	26	27	28	
%	2.5	10.5	34.5	52.5	1.06	11.11	31.22	56.61	

15: upper right second premolar; 16: upper right first molar; 17: upper right second molar; 18: upper right third molar  
 25: upper left second premolar; 26: upper left first molar; 27: upper left second molar; 28: upper left third molar

**Table 2:** Distribution of subjects according to the frequency of teeth in contact with the sinus floor

Teeth	Right side						Left side					
Number	13	14	15	16	17	18	23	24	25	26	27	28
%	0.96	10.05	27.27	21.53	13.4	26.79	1.44	6.25	32.21	19.23	14.9	25.96

13: right upper canine, 14: upper right first premolar; 15: upper right second premolar; 16: upper right first molar; 17: upper right second molar; 18: upper right third molar  
 23: left upper canine, 24: upper left first premolar; 25: upper left second premolar; 26: upper left first molar; 27: upper left second molar; 28: upper left third molar

**Table 3:** Distribution of subjects by level of anterior sinus extension

Teeth	Right sinus					Left sinus				
Number	12	13	14	15	16	22	23	24	25	26
%	0.4	15.3	42.4	35.7	5.1	0.39	15.01	40.32	35.97	8.33

12: upper right lateral incisor 13: right upper canine, 14: upper right first premolar; 15: upper right second premolar; 16: upper right first molar.  
 22: upper left lateral incisor 23: left upper canine, 24: upper left first premolar; 25: upper left second premolar; 26: upper left first molar.

**Table 4:** Distribution of subjects according to sinus floor shape

Sinus floor shape	Frequency (%)	
	Right sinus	Left sinus
Rounded	14.11	16.13
Irregular	<b>75.40</b>	<b>72.98</b>
Flat	8.87	10.08
Sloping	1.61	0.8

### 3.4. Shape of the sinus floor

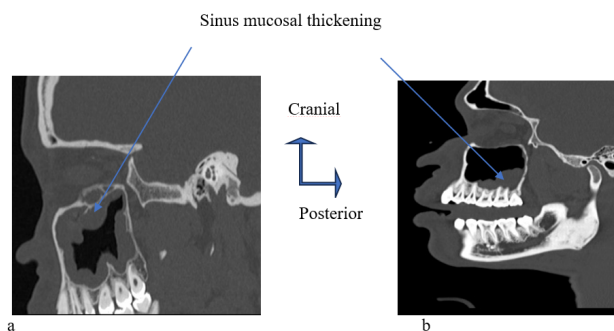
The distribution of subjects according to the shape of the sinus floor is shown in Table 4.

### 3.5. Pathological features: sinus mucosal thickening

Thickening of the right sinus mucosa was present in 79 subjects (30.9%) with a mean of  $10.18 \pm 5.56$  mm. Left sinus mucosal thickening was present in 82 cases (32.15%) with a mean of  $10.39 \pm 5.83$  mm. It was more frequent opposite to the intrasinus apex (Figure 5).

## 4. Discussion

One of the limitations of our study is that, unlike previous studies, all of which used cone beam to analyse the topographical relationships between the root apices and the sinus floor, CT was the imaging technique used in this study because cone beam computed tomography was not available in our context of a developing country with an under-equipped technical platform. However, cone beam allows a complete dental and nasosinus examination to be carried out with much greater diagnostic efficiency and lower radiation doses. In fact, it offers a much higher



**Fig. 5:** Images of sinus mucosal thickening in frame (a) and opposite the premolar-molar region (b)

resolution of bone structures while limiting the field of view and delivering radiation doses 9 to 10 times lower than those of a CT scan.<sup>21</sup>

The population was clearly male-dominated, as reported in similar studies.<sup>14,15,22–25</sup>

The mean age of the subjects was in the 5th decade, with extremes of 18 and 82 years, showing that all age groups were represented in this study. The lower limit of 18 years was related to the average age of wisdom tooth

development.

The mean sinus volume was 13 ml and was not related to gender. This result is very similar to that reported by Savi in Benin.<sup>26</sup> This author found mean sinus volumes varying between 14 and 17 ml depending on the side. He found no significant difference between the sinus volumes of male and female subjects.<sup>26</sup>

In terms of intrasinus teeth, in decreasing order of frequency, the third molars were the most common, followed by the second molars, then the first molars and finally the second premolars. This could be explained by the fact that the distance between the root apices and the sinus floor tends to decrease from the premolars to the molars.<sup>14,18,27</sup> Most authors have reported that second molars at the head of the tooth invade the sinus.<sup>5–19</sup> This difference in results could be explained by the fact that the majority of authors were only interested in the relationship between the first and second molars.<sup>6–10,14–17,27,28</sup> In our study, all teeth were evaluated in their proximity to the sinus floor. If the third molar is not included in the evaluation of the root apex-sinus floor relationship, the second molar is the most posterior tooth in the arch. In accordance with previous studies, the maxillary molars are the teeth closest to the sinus floor because the bone thickness between the maxillary sinus floor and the root apices tends to become thinner as we approach the posterior region of the maxilla.<sup>14,27–29</sup>

For teeth whose root apices were tangential to or less than 0.5 mm from the maxillary sinus floor, in decreasing order of frequency, first were the second premolars, then the third molars, followed by the first and second molars, before the first premolars and canines.

Vertical relationships, in which the teeth enter the sinus and come into contact with the floor, and horizontal relationships, in which the alveolar recess of the sinus is located in the molar furcation zone, are the most vulnerable to the maxillary sinus, both in dento-periodontal pathologies and in various odontological therapies. Whereas dental infections inoculate the sinus cavity with germs and/or toxins, iatrogenic causes mechanically irritate the sinus mucosa before becoming a microbial entry point for the sinus cavity.

The majority of anterior sinus extensions were located in the premolar region, particularly opposite the first premolar (in over 40% of cases). Kim et al. had reported a similar trend of anterior extension opposite the first premolar with 58%.<sup>30</sup> Unlike Khojatespour et al<sup>23</sup> who reported 68% sinus extension in the canine region, we found 15% anterior extension in the canine region. This proves that all teeth are potentially at risk for the maxillary sinus. Dento-periodontal therapy should be carried out with care to preserve the health of the sinus mucosa.

As for the posterior sinus extensions, they were located in the tuberosity region in 88 to 90% of cases, depending on the side. This result is very similar to that of Kim et al,<sup>28</sup> who

found that 94% of the sinuses extended into the tuberosity.

The shape of the sinus floor was irregular in 3 out of 4 cases, which may explain the position of the sinus alveolar recess, which was located in the root furcation zone of the posterior teeth.

Sinus mucosal thickening is the inflammatory response to various pathogenic attacks on the mucosa. In our study, it was present in more than 30% of cases, with an average thickness of 10 mm. The discovery of the intrusion of teeth from the canine to the 3rd molar without signs of irritation of the sinus mucosa is evidence of the role of microorganisms in the development of odontogenic maxillary sinus disease. Mechanical irritation of uninfected apices alone is not sufficient to induce inflammation of the sinus mucosa. Several authors have shown that sinus mucosal thickening is more frequent in relation to intrasinus apices with apical and/or periodontal lesions.<sup>9,16,31,32</sup>

## 5. Conclusions

This study of the proximity of the maxillary root apices to the sinus floor, carried out using CT sections of the facial mass, provided a better understanding of the teeth most frequently intruding into or in contact with the sinuses in a Beninese population. These were the most posterior teeth. In this population, molars were at greater risk of sinus disease than premolars. However, anterior sinus extensions, sometimes into the canine region, increase the number of teeth potentially at risk of sinus disease. Care should be taken with any treatment on all maxillary teeth. These results will help dental surgeons to prevent odontogenic sinus disease.

## 6. Source of Funding

None.

## 7. Conflict of Interest

None.

## References

1. Ferguson M. Rhinosinusitis in oral medicine and dentistry. *Aust Dent J.* 2014;59(3):289–95.
2. Broome M, Jaques B, Monnier Y. Dental sinusitis diagnosis and management. *Rev Med Suisse.* 2008;4:2080–4.
3. Coulibaly TD, Ba B, Coulibaly AD, Thera TD, Keita K. Odontogenic maxillary sinusitis at the CHU d'odonto-stomatologie de Bamako: 163 cases. *Afr J Dent Implantol.* 2014;3:54–60.
4. Lopes LJ, Gamba TO, Bertinato J, Freitas DQ. Comparison of panoramic radiography and CBCT to identify maxillary posterior roots invading the maxillary sinus. *Dentomaxillofac Radiol.* 2016;45(6):20160043. doi:10.1259/dmfr.20160043.
5. Psillas G, Papaioannou D, Petsali S, Dimas GG, Constantinidis J. Odontogenic maxillary sinusitis: A comprehensive review. *J Dent Sci.* 2021;16(1):474–81.
6. Oishi S, Ishida Y, Matsumura T, Kita S, Sakaguchi-Kuma T, Imamura T, et al. A cone-beam computed tomographic assessment of the proximity of the maxillary canine and posterior teeth to the maxillary

- sinus floor: Lessons from 4778 roots. *Am J Orthod Dentofacial Orthop.* 2020;157(6):792–802.
7. Regnstrand T, Torres A, Petitjean E, Lambrechts P, Benchimol D, Jacobs R. CBCT-based assessment of the anatomic relationship between maxillary sinus and upper teeth. *Clin Exp Dent Res.* 2021;7(6):197–204.
  8. Zhang YQ, Yan XB, Meng Y, Zhao YN, Liu DG. Morphologic Analysis of Maxillary Sinus Floor and its Correlation to Molar Roots using Cone Beam Computed Tomography. *Chin J Dent Res.* 2019;22(1):29–36.
  9. Goller-Bulut D, Sekerci AE, Köse E, Sisman Y. Cone beam computed tomographic analysis of maxillary premolars and molars to detect the relationship between periapical and marginal bone loss and mucosal thickness of maxillary sinus. *Med Oral Patol Oral Cir Bucal.* 2015;20(5):572–9.
  10. Jang JK, Kwak SW, Ha JH, Kim HC. Anatomical relationship of maxillary posterior teeth with the sinus floor and buccal cortex. *J Oral Rehabil.* 2017;44(8):617–25.
  11. Zhang X, Li Y, Zhang Y, Hu F, Xu B, Shi X, et al. Investigating the anatomical relationship between the maxillary molars and the sinus floor in a Chinese population using cone-beam computed tomography. *BMC Oral Health.* 2019;19(1):282–9.
  12. Jung YH, Cho BH. Assessment of the relationship between the maxillary molars and adjacent structures using cone beam computed tomography. *Imaging Sci Dent.* 2012;42(4):219–24.
  13. Pei J, Liu J, Chen Y, Liu Y, Liao X, Pan J. Relationship between maxillary posterior molar roots and the maxillary sinus floor: Cone-beam computed tomography analysis of a western Chinese population. *J Int Med Res.* 2020;48(6):300060520926896.
  14. Kwak H, Park H, Yoon H, Kang M, Koh K, Kim H. Topographic anatomy of the inferior wall of the maxillary sinus in Koreans. *Int J Oral Maxillofac Surg.* 2004;33(4):382–8.
  15. Robaian A, Alqhtani NR, Alghomlas ZI, Alzahrani A, Almalki AK, Rafedah AA, et al. Vertical relationships between the divergence angle of maxillary molar roots and the maxillary sinus floor: A cone-beam computed tomography (CBCT) study. *Saudi Dent J.* 2021;33(8):958–64.
  16. Sakir M, Yalcinkaya SE. Associations between Periapical Health of Maxillary Molars and Mucosal Thickening of Maxillary Sinuses in Cone-beam Computed Tomographic Images: a retrospective study. *J Endod.* 2020;46(3):397–403.
  17. Hameed KS, Elaleem EA, Alasmari D. Radiographic evaluation of the anatomical relationship of maxillary sinus floor with maxillary posterior teeth apices in the population of Al-Qassim, Saudi Arabia, using cone beam computed tomography. *Saudi Dent J.* 2021;33(7):769–74.
  18. Nimigean V, Nimigean VR, Măru N, Sălăvăstru DI, Bădiță D, Tuculină MJ. The maxillary sinus floor in the oral implantology. *Rom J Morphol Embryol.* 2008;49(4):485–9.
  19. Makris LML, Devito KL, D’Addazio PSS, Lima CO, Campos CN. Relationship of maxillary posterior roots to the maxillary sinus and cortical bone: a cone beam computed tomographic study. *Gen Dent.* 2020;68(2):1–4.
  20. Urooge A, Patil BA. Sexual dimorphism of maxillary sinus: A morphometric analysis using cone beam computed tomography. *J Clin Diagn Res.* 2017;11(3):67–70.
  21. Braun JJ, Riehm S. Nasosinus imaging from the most frequent to the rarest. Paris; 2012.
  22. Roques-Torres GD, Ramirez-Sotelo LR, Vaz SA, DeBoscolo S, Boscolo FN. Association between maxillary sinus pathologies and healthy teeth. *Braz J Otorhinolaryngol.* 2016;82(1):33–8.
  23. Khojatespour L, Movahhedian N, Zolghadrpour M, Mahjoori-Ghasrodashti M. Assessment of the relationship between the maxillary sinus and the canine root tip using cone beam computed tomography. *BMC Oral Health.* 2021;21:1–8. doi:10.1186/s12903-021-01700-2.
  24. Son WS, Kim YI, Kim SS, Park SB, Kim SH. Anatomical relationship between the maxillary posterior teeth and the sinus floor according to an anterior overbite. *Orthod Craniofac Res.* 2020;23(2):160–5.
  25. Yan Y, Li J, Zhu H, Liu J, Ren J, Zou L. CBCT evaluation of root canal morphology and anatomical relationship of root of maxillary second premolar to maxillary sinus in a western Chinese population. *BMC Oral Health.* 2021;21:358–66. doi:10.1186/s12903-021-01714-w.
  26. de Tovè JS. Determination of gender in a forensic context: contribution of the scanographic study of the paranasal sinuses and foramen magnum of Beninese subjects. Cotonou, Benin; 2019.
  27. Kang SH, Kim BS, Kim Y. Proximity of posterior teeth to the maxillary sinus and buccal bone thickness: a biometric assessment using cone-beam computed tomography. *J Endod.* 2015;41(11):1839–46.
  28. Gu Y, Sun C, Wu D, Zhu Q, Leng D, Zhou Y. Evaluation of the relationship between maxillary posterior teeth and the maxillary sinus floor using cone-beam computed tomography. *BMC Oral Health.* 2018;18(1):164.
  29. Yoshimine S, Nishihara K, Nozoe E, Yoshimine M, Nakamura N. Topographic analysis of maxillary premolars and molars and maxillary sinus using cone-beam computed tomography. *Implant Dent.* 2012;21(6):528–35.
  30. Kim HJ, Yoon HR, Kim KD, Kang MK, Kwak HH, Park HD, et al. Personal-computer-based three-dimensional reconstruction and simulation of maxillary sinus. *Surg Radiol Anat.* 2002;24(6):393–9.
  31. Arijji Y, Obayashi N, Goto M, Izumi M, Naitoh M, Kurita K, et al. Roots of the maxillary first and second molars in horizontal relation to alveolar cortical plates and maxillary sinus: computed tomography assessment for infection spread. *Clin Oral Investig.* 2006;10(1):35–41.
  32. Lu Y, Liu Z, Zhang L, Zhou X, Zheng Q, Duan X, et al. Associations between maxillary sinus mucosal thickening and apical periodontitis using cone-beam computed tomography scanning: a retrospective study. *J Endod.* 2012;38(8):1069–74.

## Author biography

**Sylvie Arlette Bancole Pognon**, Assistant Professor

**Mamadou Diatta**, Assistant Professor

**Mamadou Lamine Ndiaye**, Professor

**Mohamed Djivede Akanni**, Professor

**Babacar Tamba**, Professor

**Francois Avakoudjo**, Professor

**Patricia Yekpe Ahouansou**, Professor

**Soukeye Dia Tine**, Professor

**Wassi Adjibabi**, Professor

**Cite this article:** Pognon SAB, Diatta M, Ndiaye ML, Akanni MD, Tamba B, Avakoudjo F, Ahouansou PY, Dia Tine S, Adjibabi W. Topographic study of antral teeth on computed tomography in a beninese population. *J Oral Med, Oral Surg, Oral Pathol, Oral Radiol* 2023;9(3):1-6.