

P9

Diffuse Cervico-Facial Cellulitis:
Epidemiological, Diagnostic and Therapeutic
Aspects at the Teaching Hospital CNHU HKM
of Cotonou

Ulrich Bidossèssi Vodouhe, Nesrine Gouda,
Alexis Do Santos Zounon, Romaric Beheton,
Sonia Lawson Afouda, François Avakoudjo,
Wassi Adjibabi, Bernadette Vignikin
Yehouessi

International Journal of Otolaryngology and
Head & Neck Surgery,

2022, 11, 266-276

DOI ou Site Web de l'article :

www.scirp.org/journal/ijohns

Bases de données d'indexation h5-index &
Ranking

Library Hub Discover

About

Search

Advanced Search

Support

[Discover](#) > [Search result](#) > Record 1 of 1 for 2168-5452

Help

International journal of otolaryngology and head & neck surgery

⏪ ⏩ [Back to results](#) ⏪ ⏩

Other titles: Int. j. otolaryngol. head neck surg. (Online)
International journal of otolaryngology and head and neck surgery
IJOHNS

Frequency: Quarterly
Quarterly

Published: Irvine, CA : Scientific Research Publishing, Inc.

ISSN: 2168-5460

periodical

🖥 E-resource

[Disable Google Preview](#)

ISSN: 2168-5452 Volume 11, Number 5, September 2022



International Journal of Otolaryngology and Head & Neck Surgery



ISSN: 2168-5452



<https://www.scirp.org/journal/ijohns>

Journal Editorial Board

ISSN 2168-5452 (Print) ISSN 2168-5460 (Online)

<https://www.scirp.org/journal/ijohns>

Editor-in-Chief

Prof. Murthy P. S. N. Institute of Medical Sciences and Research Center, India

Editorial Board

Prof. Rayleigh Ping-Ying Chiang Taipei Veterans General Hospital, China

Prof. Anthony J. Cmelak Vanderbilt University, USA

Dr. Yubing Dai University of Houston, USA

Prof. Padmavathi Devi Guntur Medical College, India

Dr. David Livingstone Alves Figueiredo University of Midwest, Brazil

Prof. Kevin McLoughlin Patrick Higgins Sunnybrook Health Sciences Centre, Canada

Prof. Kris R. Jatana The Ohio State University, USA

Dr. Jizhen Lin University of Minnesota Medical School, USA

Prof. Prepageran Narayanan University Malaya Medical Center, Malaysia

Prof. David K. Ryugo Garvan Institute of Medical Research, Australia

Prof. Nishi Sonkhya S.M.S. Medical College & Attached Hospitals, India

Prof. M. S. Vidyasagar Father Muller Medical College Hospital, India

Prof. B. Viswanatha Kasturba Medical College, India

Table of Contents

Volume 11 Number 3

May 2022

Facial and Orbital Emphysema after a Violent Nose-Blowing

A. Lachkar, A. Salek, D. Benfadil, F. Elayoubi, M. R. Ghailan.....107

Ramsay Hunt Syndrome Revealing HIV Conditions

G. N. Ngniee Tafo, F. I. Kone, B. Maiga, M. Keita.....112

Otological Injuries Observed in Head and Neck Trauma in a Second-Line Hospital

G. N. Ngniee Tafo, K. F. Issa, S. Djibril, T. S. Karim, K. Mohamed.....119

An Unusual Cervical Penetrating Wound Extended to the Right Pleural Dome

U. B. Vodouhe, J. C. Apouakone, A. Do Santos Zounon, D. Guezo, S. L. Afouda, F. Avakoudjo,
W. Adjibabi, B. V. Yehouessi.....126

Facial and Periorbital Emphysemas Following a Violent Sneezing: An Atypical Clinical Situation

A.-R. Ngo Nyeki, C. Mvilongo, E. M. Ngom, V. Fokouo, R. Meva'a, L. Atanga, Y. Mossus, C. Nkidiaka,
L. Meka, A. Taimou, S. Abogo, D. Mindja, O. Ngaba, G. Koki, F. Djomou, R. Njock.....136

Diffuse Cervico-Facial Cellulitis: Epidemiological, Diagnostic and Therapeutic Aspects at the Teaching Hospital CNHU HKM of Cotonou

Ulrich Bidossèssi Vodouhe, Nesrine Gouda, Alexis Do Santos Zounon, Romaric Beheton,
Sonia Lawson Afouda, François Avakoudjo, Wassi Adjibabi, Bernadette Vignikin Yehouessi

Faculty of Health Sciences, University of Abomey-Calavi (R. BENIN), Cotonou, Republic of Benin

Email: bidulrich@yahoo.fr

How to cite this paper: Vodouhe, U.B., Gouda, N., Zounon, A.D.S., Beheton, R., Afouda, S.L., Avakoudjo, F., Adjibabi, W. and Yehouessi, B.V. (2022) Diffuse Cervico-Facial Cellulitis: Epidemiological, Diagnostic and Therapeutic Aspects at the Teaching Hospital CNHU HKM of Cotonou. *International Journal of Otolaryngology and Head & Neck Surgery*, 11, 266-276. <https://doi.org/10.4236/ijohns.2022.115028>

Received: August 8, 2022

Accepted: September 25, 2022

Published: September 28, 2022

Copyright © 2022 by author(s) and Scientific Research Publishing Inc. This work is licensed under the Creative Commons Attribution International License (CC BY 4.0).

<http://creativecommons.org/licenses/by/4.0/>



Open Access

Abstract

Purpose of the work: to study the epidemiological, clinical and therapeutic aspects of diffuse cervico-facial cellulitis collected within the ENT-CCF surgery department of the CNHU of Cotonou. Materials and method: the study was a descriptive retrospective carried out from January 1st, 2018 to December 31st, 2020. It concerned new cases of diffuse cervico-facial cellulitis identified during the period. Results: in 3 years, 55 cases of diffuse cervico-facial cellulitis were identified out of 1101 hospitalized patients. The frequency was 4.99%. Per year, 18 cases of cervico-facial cellulitis are recorded. The mean age of the patients was 41.3 years with extremes of 15 years and 85 years. A clear male predominance was noted with a sex ratio of 1.29. Painful cervico-facial swelling was the most common reason for medical consultation (47 patients or 85.5% of cases). Thirty patients (54.5%) showed a deterioration in general condition. Several clinical forms of diffuse cervico-facial cellulitis have been described, in particular the gangrenous form, the suppurative, necrotizing form and LUDWIG's angina. The portal of entry was dental in 50 patients (91% of cases), favored by poor oral hygiene and self-medication with non-steroidal anti-inflammatory drugs (NSAIDs). The medico-surgical treatment implemented was favorable for 47 patients (85.5%). Conclusion: Diffuse cervico-facial cellulitis remains a frequent medical-surgical emergency in the CCF ENT department at the Teaching Hospital of Cotonou. Mainly of odontogenic origin, it is encountered in different clinical forms.

Keywords

Diffuse Cellulitis, Cervico-Facial, Odontogenic, Antibiotic Therapy, Incision

Drainage

1. Introduction

Diffuse cervico-facial cellulitis (CCF) or diffuse fasciitis is an inflammation of the cellulo-adipose tissues of the neck and face, often of a polymicrobial nature with an extensive tendency by propagation along the various cervical aponeuroses [1]. These are polymicrobial infections involving aerobic and anaerobic germs [2] [3]. The portal of entry is most often located in the bucco-dental or pharyngeal region, with direct contamination of the cervical region by transmuco-sal route, unlike infections by lymphatic or hematogenous spread [3]. True diffuse fasciitis is to be differentiated from diffuse cellulitis. The latter are initially circumscribed cellulitis, which have spread to the neighboring facial or even cervical compartments. The latter lack the rapidly extensive necrosis component [2]. Treatment combines [3] [4] antibiotic therapy, drainage of the purulent collection and treatment of the cause [5]. In this study, we took into account both diffuse cellulite and true diffuse cellulite. CCF is associated with potentially significant morbidity and mortality, and it always remains a medical-surgical emergency [3] [4]. In view of the morbidity and mortality linked to this pathology, [5] [6] [7], we proposed to study its epidemiological, diagnostic and therapeutic aspects in a hospital environment in our practice context.

2. Material and Method

The study was descriptive, retrospective and took place from January 1st, 2018 to December 31st, 2020. All the patients who consulted in the ENT-CCF department at the National Teaching Hospital of Cotonou during the study period, and in whom the diagnosis of diffuse cervico-facial cellulitis was retained then the therapeutic management carried out. Diffuse cervico-facial cellulitis was evoked on clinical grounds. It was a diffuse, sensitive, hot cervico-facial swelling with a taut, shiny, dark, fissured or necrotic skin covering. Suffusion of pus and evidence of necrotic subcutaneous tissue were characteristic. Were excluded, Cases of circumscribed cervical or facial cellulitis, as well as incomplete or unlocated medical records. The parameters studied were: age, sex, profession, consultation time, reason for consultation, history, functional, general and physical signs, data from paraclinical examinations, treatment received complications evolution. Data collection was done using a pre-established and tested counting sheet. Data entry was performed using Epi Data 3.1 software and analysis using Epi info 3.5.3 software. The interpretation was carried out by comparing the means obtained. The confidentiality of the identity of the patients was respected.

During the study, we had as difficulties, incomplete or not found files as well as badly filled files, without precision on the description of the clinical examination.

3. Results

3.1. Epidemiological Aspects

In 3 years, 55 patients were followed for diffuse cervico-facial cellulitis. The annual incidence was 18.33 cases per year. For a total of 1101 patients hospitalized in the department during the period, cases of diffuse CCF accounted for 4.99%.

Figure 1 shows the distribution of cases by age and sex.

The mean age was 41 years with a standard deviation of 15.1. The youngest patient was 15 years old and the oldest 85 years old. The predominance was male with a rate of 56.4% (31 men for 24 women) or a sex ratio of 1.29. Various professions have been listed. **Table 1** shows the distribution of patients according to their occupation.

3.2. Diagnostics

The most common reason for consultation was painful cervico-facial swelling: 47 cases or 85.5% of cases. Dyspnea and skin necrosis were noted respectively by 5 and 3 patients, *i.e.* 9.10% and 5.4%.

The duration of evolution of the symptomatology was listed in the study. **Table 2** shows the breakdown.

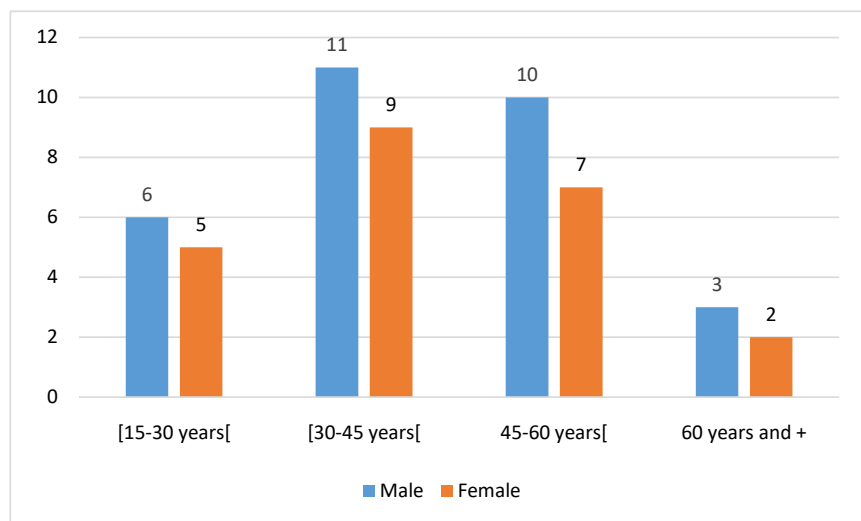


Figure 1. Distribution of patients by age and gender.

Table 1. Distribution of patients according to their occupation.

Occupation	Number	Percentage
Craftsman	29	52.7
Retailer	12	21.8
Civil servant	07	12.7
House worker	04	07.3
Student /pupil	03	05.5
Total	55	100.0

All the patients have started medication before going to hospital. Nonsteroidal anti-inflammatory drugs (NSAIDs) were used by 44 patients, *i.e.* 80% of cases, antibiotics were associated with NSAIDs by 26 patients, *i.e.* 47.3%. Traditional therapy was practiced by 8 patients, *i.e.* 14.5%. The latter brought together various practices, namely herbal teas, scarifications, poultices, herbal intraoral massages. Painful cervico-facial swelling was the most common reason for medical consultation (47 patients or 85.5% of cases).

The main risk factors identified were poor oral hygiene, auto-medication with non-steroidal anti-inflammatory drugs and diabetes. Different clinical signs were recorded. **Table 3** highlights the characteristics of the different cases listed.

The injured teeth were molars. NSAIDs were taken by self-medication in the context of dental pain.

Table 4 summarizes the germs identified in the pus samples and their sensitivity to antibiotics.

Image 1 highlights the cervico-facial necrosis which allows the diagnosis of diffuse cervico-facial cellulitis to be made.

Image 2 includes CT sections of one of the patients, allowing the diagnosis of mediastinitis complicating a diffuse cervico-facial cellulitis.

Table 2. Distribution of patients according to consultation time.

Consultation duration (days)	Number	Percentage
[0 - 7[09	16.3
[7 - 15]	18	32.7
[16 and more [28	51.0
Total	55	100.0

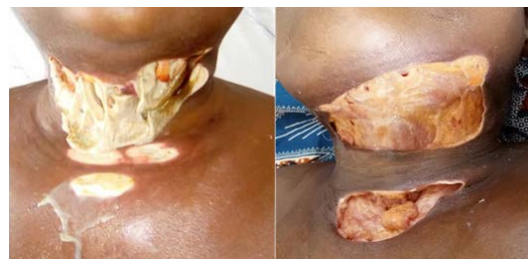
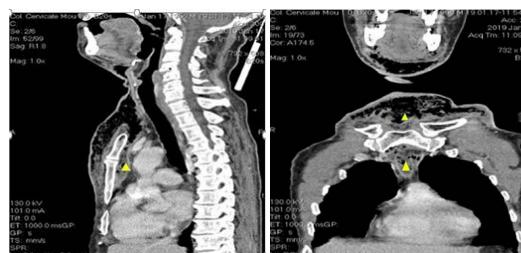
Image 1. Necrotic lesions in a case of a diffuse cervico-facial cellulitis.



(a)

(b)

Image 2. (a) Retro-sternal collection on computed tomography, suggesting a mediastinitis complicating a diffuse CCF. (b) Hyperdense image with supra-clavicular and supra-aortic gas traps reflecting mediastinitis.

Table 3. Clinical and paraclinical characteristics of CCFs.

	Number	%
Origin of the cellulitis		
<i>Dental</i>	50	91
<i>Oropharyngeal</i>	03	4
<i>Cutaneous</i>	02	5
NSAIDs taking	44	80
Diabetes	06	15
Pregnancy	03	05.5
Clinical signs		
General health alteration	30	54.5
Fever	48	87.3
Dyspnea	22	40
Dysphagia	18	32.7
Thoracic pain	14	25.5
Coughing	14	25.5
Septic shock signs	25	40
Consciousness alteration		
Trismus	42	76.4
Oedema of the floor of the mouth	23	41.8
Clinical forms of CCF		
Gangrenous	19	34.5
Suppurative	16	29.1
Necrosis	12	21.8
Ludwig's angina	08	14.5
Paraclinical signs		
Dental fissure	22	78.6
Apical granuloma	5	17.9
Mediastinitis	17	
Anemia	30	75
Hyperleucocytose	39	97.5
HIV positive serology	04	07.3

Table 4. Distribution of germs according to sensitivity to antibiotics.

Identified Germs n = 41	Number (%)	Sensitivity
<i>Streptococcus sp</i>	14 (34.15)	Ceftriaxone-lincomycine-amoxicillin acid clavulanic
<i>Streptococcus beta hemolytic</i>	10 (02.44)	Ceftriaxone-lincomycine amoxicillin acid clavulanic
<i>Echerichea coli</i>	07 (17.07)	Ceftriaxon-ciprofloxacin
<i>Pseudomonas aeruginosa</i>	06 (14.63)	Lincomycine-levofloxacin
<i>Klebsial pneumoniae</i>	02 (04.88)	Ciprofloxacin-Fosfomycin
<i>Staphylococcus aureus</i>	02 (04.88)	Ceftriaxon-amoxicillin acid clavulanic-mipeneme

3.3. Therapeutic Aspects

The treatment was medical-surgical in all cases. The surgery consisted of an incision draining the pus (45 patients or 81.8%). It was performed under general anesthesia in 2 cases or 3.6%. Necrotic tissue was stripped and daily dressing was performed in all cases. Depending on the sensitivity of the germs in question, a bi or triple antibiotic therapy was administered parenterally then orally when the symptomatology improved. Antibiotic therapy was initially probabilistic. The combination of third-generation cephalosporin and demetronidazole was administered to 39 patients, *i.e.* 70.9% of cases. An aminoglycoside was added in 4 patients, *i.e.* 7.2% of cases.

Mechanotherapy was performed in cases of trismus. A stomatological consultation for dental care was carried out in cases of odontogenic cellulitis. The evolution was favorable for 47 patients or 85.5% of cases. Sequelae such as retractile scars and keloids were observed in 5 patients (9.1%). Two cases of orostoma (*i.e.* 3.6%) were recorded. Eight patients or 14.5% of cases died during hospitalization in septic shock in the tables.

4. Discussion

The incidence of CCFs is highly variable in the literature. This study found a mean of 18 cases per year. This figure is higher than that of Bouraima *et al.* in Parakou in northern Benin [7] who reported 14 cases per year. Lower frequencies had been noted in previous studies by Kpemissi in Togo in 1995 [8] and Lawson *et al.* [6] in Benin in 2012, with 8 cases per year and 7 cases per year respectively. Badou *et al.* [9] in Ivory Coast had noted a hospital prevalence of cellulitis of 3.5% with an annual incidence of 4.3 cases. These figures show that the prevalence of the disease is on the rise in the sub-Saharan region. The increase could also be linked to better care seeking by the community in recent years. Higher incidences have been reported by authors in northern countries. Indeed, Tran Ba Huy *et al.* in France [10] identified an average of 30 cases per year. Similarly in Morocco, Rouadi *et al.* collected 43 cases per year [11].

The cervical scar after healing can be unsightly. **Image 3** is the photography of a patient after recovery

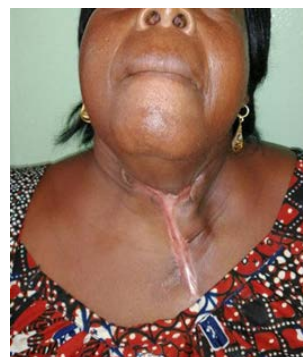

Image 3. Retractable cervicothoracic scar after diffuse CCF.

From this study, it appears that young adults were the most affected by CCF with an average age of 41 years (**Figure 1**). This finding is consistent with those of Ngouoni *et al.* [12] in Congo and Rakotoarison *et al.* [13] in Madagascar with average ages of 28 and 31 years respectively. Other authors have also reported a greater attack on individuals in their forties [4] [5] [14] [15].

Male subjects were the most affected in this study (**Figure 1**). The same was true in the work of Keita *et al.* [4] as well as Ngouoni *et al.* [12]. The male predominance found in the literature could be explained by the fact that women have a better immune response in various studies, including that of Rose *et al.* [16].

From this survey, the most vulnerable populations were those with low incomes (**Table 1**). The same remark was made by Konsem *et al.* in Ouagadougou [17] where 84.6% of patients exercised professions with a low socio-economic level (craftsmen, farmer). Other studies in the sub-region had found the same finding [9] [18]. It emerges from these various observations that the low-income socio-professional strata were the most affected.

Self-medication with NSAIDs was the main risk factor identified in this study (**Table 3**). The use of NSAIDs before the onset of CCF has been reported several times in previous works. This is the case of Miloundja *et al.* [3] in Gabon (87.5% NSAID use), EL Ayoubi *et al.* [19] in Morocco (48.3% NSAID use). The same findings were made by Salami *et al.* [20], in Treichville where 67.8% of patients self-medicated with NSAIDs, over an average duration of 5.6 days with extremes of 1 to 17 days. Hounkpatin *et al.* [21] in Parakou noted that the supply was done in pharmacies for 59.1% of patients. Indeed, NSAIDs have the advantage of calming the patient's pain and fever, however, by inhibiting cyclo-oxygenase and they prevent the release of prostaglandins (mediators of inflammation) and thus reduce the patient's immune defense [2]. They are the main factors backing the extension of CCF [3] [10] [22]. Due to their affordability and accessibility, they have been the first therapeutic resort for most patients.

Diabetes mellitus is a significant risk factor (**Table 3**). It concerned 15% of patients in this series. According to Hernandez *et al.* [23], diabetes mellitus was the first risk factor followed in decreasing order by alcoholism, smoking and chemotherapy. Badou *et al.* [9] noted HIV infection (9.6%) and diabetes (2.7%) as risk factors. HIV infection was also recorded in this study in 7.3% of cases. The resulting immunosuppression could justify the vulnerability of the terrain and the proliferation of germs responsible for cellulite. Aswan *et al.* [22] noted a hospital frequency of facial cellulitis added to diabetes of 9.8%; with 53% of patients discovering their diabetic state by chance. A systematic fasting glycaemia would therefore make it possible to identify and manage certain cases of diabetes in the face of cervico-facial cellulitis. Several authors [22] [23] agree that diabetes defines the induction and progression of cellulite; it produces leukocyte dysfunction, reduces phagocytosis chemotaxis. Additionally, hyperglycemia, a hallmark of diabetes mellitus, suppresses the immune system and enhances bacterial growth. A vicious circle is thus formed, infection-diabetes-infection. From our

results, 5.5% of patients are pregnant. For Pucci Resi *et al.* [24], odontogenic infections have potentially harmful effects on pregnant women and therefore on fetal development. Of these odontogenic affections, it was counted: cervico-facial cellulitis in 30% of cases, Ludwig's angina in 27.5%, abscess (submandibular and submental) in 23.2%, deep cervical suppuration complicated by mediastinitis in 17.8% and cerebral abscess in 1.5%. In fact, pregnancy is a period of relative maternal immunosuppression, making the body more susceptible to infections.

Human gingiva has been shown to be a target tissue for increases in estrogen and progesterone and estradiol-affected periodontal microvasculature that contribute to oral tissue alterations. Oral health is thus compromised during pregnancy due to all the hormonal factors and the significant alteration of the bacterial mass of the oral cavity, with a tendency towards a more anaerobic flora [25] [26]. The almost constant cervico-facial swelling was inflammatory and painful. On its own, it is evocative of cellulite. Several authors, notably Benzarti *et al.* [27], and Blancal *et al.* [28], have pointed out that painful cervico-facial swelling was the main reason for consultation in their series. The gangrenous CCF, characteristic by these snowy crepitations was objectified in approximately 34.5% of the cases. On the other hand, phlegmonous cellulitis was more represented in the work of Njifou *et al.* [29] in Cameroon (82%), Thiebaut *et al.* [30] in Dijon (82.3%). Forty percent (40%) of patients in this series had dyspnoea, sometimes accompanied by cough and chest pain. These signs of gravity made suspect: a diffuse CCF complicated by mediastinitis. Mediastinitis has been confirmed for some patients. In Morocco, Rouadi *et al.* [11] noted among the complications, 11% of mediastinitis and 1 case of thrombophlebitis of the internal jugular vein. These complications of mediastinitis, severe sepsis, and thrombophlebitis of the jugular vein were identified by Tran Ba Huy *et al.* in respectively 31%, 47% and 16% [10]. The high prevalence (91%) of dental origin was unanimously reported by authors such as Rakotoarison *et al.* [13] in Madagascar (74%) and Diallo *et al.* in Guinea Conakry (68%) [31].

Kouakou *et al.* [32] in Cote d'Ivoire mentioned in addition to dental caries (91.30%), skin infections (5.80%) and mandibular fractures (2.90%). The infected teeth causing more diffuse CCF were the molars in this study. This same remark was made by Sette Dias *et al.* [33] in Brazil and Obimakinde *et al.* [34] in Nigeria. Biologically, hyperleukocytosis with neutrophilic predominance was classic according to the authors [3] [27] [32] [34]. In the cultures of the series, a bacterial polymorphism with a predominance of aero-anaerobic saprophytic germs of the oral cavity was noted. The same germs were identified by Njifou *et al.* [29]. Panoramic dental radiography made it possible to objectify the causal tooth(s) (caries, radiolucent apical images, wisdom teeth included) and to rule out any mandibular causes as recommended by El Ayoubi *et al.* [19]. Medical treatment preceded and accompanied the surgical management of cervico-facial cellulitis. It revolved around resuscitation measures and antibiotic therapy. He also took into account the patient's comorbidities. Antibiotic therapy was initially probabilistic and parenteral. For most authors, triple antibiotic therapy

was appropriate: beta-lactam, imidazole and aminoglycosides [11] [13] [28]. With the antibiogram from the ECB result, other classes of antibiotics were used such as quinolones (Table 4).

Diffuse CCF requires flattening of all suppurated or necrotic areas. This implies a wide and extensible approach [19] [27]. In this study, surgical treatment was performed in 81.8% of cases. This result is similar to the conclusions of the series by Keita *et al.* [4] in Mali and by Rouadi *et al.* [11] in Morocco, which surgically took into account respectively 81% and 86% of cases. The drainage incision under anesthesia allows good resection of necrotic areas, facilitates washing, and thus promotes a rapid drying up of suppuration [8] [13]. General anesthesia was performed in 3.6% of cases in this study. In Madagascar, on the other hand, Rakotoarison *et al.* reports that 83.3% of patients benefited from a drainage incision under general anesthesia [13]. As soon as the general condition improved and the trismus regressed, patients with dental or periodontal lesions were referred for stomatological consultation. Bouraima *et al.* [7], as well as Lawson *et al.* [6] adopted the same attitude for odontogenic cellulitis. The case fatality rate of diffuse CCF was 14.5% in this study. Some authors have reported higher rates. Diallo *et al.* recorded 21% deaths [31], Keita *et al.* reported 28% deaths [18]. Despite the patient's defects, these high scores are also explained by the delay in the consultation and the lack of means to access the prescribed treatment [4] [31].

5. Conclusion

The diffuse CCF is a serious condition in young adult males. The most common contributing factors were poor oral hygiene, use of NSAIDs, diabetes and HIV infection. It was essentially of dental origin. Complications such as septic shock and mediastinitis were frequent and very rapidly fatal. It is a medical-surgical emergency. Early and appropriate antibiotic therapy is necessary for the evolution of a cure.

Conflicts of Interest

The authors declare no conflicts of interest regarding the publication of this paper.

References

- [1] Potard, G., Marianowski, R., Fortun, C. *et al.* (2000) Cellulites de la face et du cou: À propos de 13 cas. *Journal Français d'Oto-Rhino-Laryngologie*, **49**, 325-327.
- [2] Peron, J.M. and Mangez, J.F. (2002) Cellulites et fistules d'origine dentaire. *Encyclopédie Médico-Chirurgicale (Editions Scientifiques et Médicales Elsevier SAS, Paris)*, 22-033-A-10, 14.
- [3] Miloundja, J., Eyogho, S., Lawson, J., *et al.* (2011) Cellulites cervico-faciales diffuses: 32 cas vus à Libreville. *Santé*, **21**, 153-157. <https://doi.org/10.1684/san.2011.0256>
- [4] Keita, M., Diango, D., Doumbia, K., Diallo, M., *et al.* (2008) La Cellulite Cervicale extensive en milieu hospitalier sub-sahélien une pathologie oubliée? Cas du Mali. *Médecine d'Afrique Noire*, **55**, 8-9.

- [5] Hounkpe, Y., Oussa, G., Vodouhe, S., *et al.* (1990) Les cellulites cervico-faciales à propos de 55 cas colligés dans les services d'ORL et d'ophtalmologie du CNHU de Cotonou. *Médecine d'Afrique Noire*, **37**, 29.
- [6] Afouda, S.L., Avakoudjo, F., Alamou, S., *et al.* (2012) Aspects étiolo-épidémiologiques et thérapeutiques des cellulites cervico-faciales d'origine dentaire. *Revue de Laryngologie Otologie Rhinologie*, **133**, 197-200.
- [7] Bouraïma, F.A., Hounkpatin, S., Vodouhe, U. and Flatin, M. (2019) Aspects diagnostiques et thérapeutiques des cellulites cervico-faciales à Parakou, Bénin. *Journal de la Recherche Scientifique de l'Université de Lomé (Togo)*, **21**, 299-307.
- [8] Kpemissi, E. (1995) Cellulites cervico faciales d'origine bucco-dentaire: Étude de 26 cas au CHU de Lomé. *Revue de Laryngologie Otologie Rhinologie*, **116**, 195-197.
- [9] Badou, K., Buraima, F., Yoda, M., Traore, K., *et al.* (2014) Cervicofacial cellulitis in the teaching hospital of yopougou (Abidjan-Côte-D'ivoire). *Revue Internationale du Collège d'Odonto-Stomatologie Africain et de Chirurgie Maxillo-Faciale*, **21**, 5-10.
- [10] Huy, P.T.B., Blancal, J.P., Verillaud, B., *et al.* (2011) Les cellulites cervico-faciales: Une grave urgence ORL. *Bulletin de l'Académie Nationale de Médecine*, **195**, 661-678. [https://doi.org/10.1016/S0001-4079\(19\)32072-2](https://doi.org/10.1016/S0001-4079(19)32072-2)
- [11] Rouadi, S., Ouaiissi, L., El Khiati, R., *et al.* (2013) Les cellulites cervico-faciales à propos de 130 cas. *Pan African Medical Journal*, **14**, 1-5. <https://doi.org/10.11604/pamj.2013.14.88.1477>
- [12] Ngouoni, B., Ngotne, R., Mbisi-Ngoma, H. and Mosimbi, N. (2008) Cellulite diffuses sous-mandibulaires d'origine dentaire. *Revue Internationale du Collège d'Odonto-Stomatologie Africain et de Chirurgie Maxillo-Faciale*, **15**, 38-42.
- [13] Rakotoarison, R., Ramarozatovo, N., Rakoto, F. and Rakotovao, F. (2008) Cellulites cervico-faciales: À propos de 41 cas. *Médecine Buccale Chirurgie Buccale*, **14**, 35-39. <https://doi.org/10.1051/mbcb/2008012>
- [14] Barnabe, D., Briche, T. and Raynal, M. (2003) Les cellulites cervicales. *Revue Africaine d'ORL et de Chirurgie Cervico Facial*, **77**, 8-12.
- [15] Cruz Toro, P., Callejo Castillo, À., Tornero Altó, J., *et al.* (2014) Cervical Necrotizing Fasciitis: Report of 6 Cases and Review of Literature. *European Annals of Otorhinolaryngology, Head and Neck Diseases*, **131**, 357-359. <https://doi.org/10.1016/j.anorl.2013.08.006>
- [16] Rose, C., Tellion, C., Ferri, F. and Donazzan, M. (1997) Les cellulites faciales graves diffuses. *Revue de Stomatologie et de Chirurgie Maxillo-Faciale*, **98**, 269-271.
- [17] Konsem, T., Millogo, M., Ouedraogo, D., *et al.* (2012) Les cellulites diffuses cervico-faciales au centre hospitalier universitaire Yalgado Ouedraogo (Ouagadougou). *Revue Internationale du Collège d'Odonto-Stomatologie Africain et de Chirurgie Maxillo-Faciale*, **19**, 30-34.
- [18] Keïta, A., Fofana, M., Diallo, I., *et al.* (2018) Les cellulites cervico-faciales: Facteurs favorisants, aspects épidémiologique, clinique, thérapeutique et évolutif au service d'Otorhinolaryngologie et de Chirurgie Cervico-Faciale de l'Hôpital Régional de Kankan, Guinée-Conakry. *JACCR Africa*, **2**, 261-268.
- [19] El Ayoubi, A., El Ayoubi, F., Mas, E., *et al.* (2009) Cellulites cervico-faciales diffuses d'origine dentaire: À propos de 60 cas. *Médecine Buccale Chirurgie Buccale*, **15**, 127-135. <https://doi.org/10.1051/mbcb/2009011>
- [20] Salami, A., Assouan, C., Adouko, J., *et al.* (2017) Anti-inflammatoires vendus dans la rue et cellulites cervico-faciales odontogènes au CHU de Treichville (côte d'ivoire). *Revue Internationale du Collège d'Odonto-Stomatologie Africain et de*

Chirurgie Maxillo-Faciale, **24**, 42-44.

- [21] Hounkpatin, S., Flatin, M., Avakoudjo, F., et al. (2015) Automédication en ORL au centre hospitalier départemental du Borgou à Parakou dans le nord Bénin. *Revue Africaine d'ORL et de Chirurgie Cervico Facial*, **15**, No. 1.
- [22] Assouan, C., Anzouan, K., Aka-Adouko, J., et al. (2012) Prise en charge des cellulites chez le diabétique. *Revue Internationale du Collège d'Odonto-Stomatologie Africain et de Chirurgie Maxillo-Faciale*, **19**, 16-19.
- [23] Hernandez, D., Manuel, A., Chavez, G. and Rivera, A. (2017) Facial Necrotizing Fasciitis in Adults: A Systematic Review. *Heighpubs Otolaryngology and Rhinology*, **1**, 20-31.
- [24] Pucci, R., Cassoni, A., Carlo, D., et al. (2021) Severe Odontogenic Infections during Pregnancy and Related Adverse Outcomes. Case Report and Systematic Literature Review. *Tropical Medicine and Infectious Disease*, **6**, Article 106. <https://doi.org/10.3390/tropicalmed6020106>
- [25] Wong, D., Cheng, A., Kunchur, R., et al. (2012) Management of Severe Odontogenic Infections in Pregnancy. *Australian Dental Journal*, **57**, 498-503. <https://doi.org/10.1111/j.1834-7819.2012.01728.x>
- [26] Ali, E., Eltayeb, A. and Osman, M. (2020) Delay in the Referral of Pregnant Patients with Fascial Spaces Infection: A Cross-Sectional Observational Study from Khartoum Teaching Dental Hospital, Sudan. *Journal of Maxillofacial and Oral Surgery*, **19**, 298-301. <https://doi.org/10.1007/s12663-019-01206-z>
- [27] Benzarti, S., Mardassi, A., Mhamed, R., et al. (2007) Les cellulites cervico-faciales d'origine dentaire: À propos de 150 cas. *Journal Tunisien d'ORL et de Chirurgie Cervico-Faciale*, **19**, 24-28. <https://doi.org/10.4314/jtdorl.v19i1.57887>
- [28] Blancal, J.-P., Kania, R., Sauvaget, E., et al. (2010) Prise en charge des cellulites cervico-faciales en Réanimation. *Réanimation*, **19**, 297-303. <https://doi.org/10.1016/j.reaurg.2010.04.001>
- [29] Njifou, N.A., Essama, L., Kouotou, E., et al. (2014) Cellulites cervico-faciales en milieu hospitalier Camerounais. *Health Sciences and Disease*, **15**, 1-4.
- [30] Thiebaut, S., Duvillard, C., Romanet, P., et al. (2010) Management of Cervical Cellulitis with and without Mediastinal Extension: Report of 17 Cases. *Revue de Laryngologie Otologie Rhinologie*, **131**, 187-192.
- [31] Diallo, O.R., Balde, N.M., Conde, B., et al. (2006) Les cellulites cervico-faciales chez le patient diabétique au CHU de Conakry. *Revue Internationale du Collège d'Odonto-Stomatologie Africain et de Chirurgie Maxillo-Faciale*, **13**, 13-16.
- [32] Kouakou, K., Ouattara, B., Sidibé, O., et al. (2018) Cellulites cervico-faciales diffusées et nécrosantes: Aspects épidémiologiques, cliniques et thérapeutiques en 15 ans au CHU de Cocody (Côte d'Ivoire). *Revue Internationale du Collège d'Odonto-Stomatologie Africain et de Chirurgie Maxillo-Faciale*, **25**, 5-9.
- [33] Sette-Dias, A., Maldonado, A., Aguiar, E., et al. (2012) Profile of Patients Hospitalized with Odontogenic Infections in a Public Hospital in Belo Horizonte, Brazil. *Journal of Clinical and Experimental Dentistry*, **4**, e271-e274. <https://doi.org/10.4317/jced.50856>
- [34] Obimakinde, O., Okoje, V.N., Akinmoladun, V.I., Fasola, A., et al. (2012) Retrospective Evaluation of Necrotizing Fasciitis in University College Hospital, Ibadan. *Nigerian Journal of Clinical Practice*, **15**, 344-348. <https://doi.org/10.4103/1119-3077.100644>