

Surgical Treatment of a Case of Carotid Mycotic Aneurysm

Wilfried Elohonnan Gandji^{1*}, Pape Adama Dieng², Gilles Setondji Attolou¹, Serge Mewanou³, Habib N'domè Natta N'tcha¹, Delphin Kuassi Mehinto¹

¹Visceral surgery department of Hubert Koutoukou University Hospital Center Maga Cotonou, Benin

²Department of Thoracic and Cardiovascular Surgery of Fann Dakar, Senegal

³Anesthesia and intensive care unit of the Hubert Koutoukou Maga National University Hospital Center, Benin

*Corresponding author

Wilfried Elohonnan Gandji

Article History

Received: 03.11.2018

Accepted: 06.11.2018

Published: 30.11.2018

DOI:

10.21276/sjmcr.2018.6.11.15



Abstract: False aneurysm of the common carotid artery is regularly reported, but here we report a rare case of false aneurysm induced by tuberculous mycobacteria of the common carotid artery. This is a 26-year-old patient with a pulsatile left cervical lobe. The patient had a history of cervical lymphadenopathy, the biopsy of which revealed a tuberculous mycobacterium infection. The rapid increase in the size of the mass motivated the realization of an ultrasound then a cervical CTA that made it possible to make the diagnosis of a false aneurysm of the common carotid artery. The patient underwent open surgery of the false aneurysm with placement of a venous patch. The postoperative course was simple.

Keywords: Carotid, Infection, Tuberculous mycobacteria, false aneurysm, vascular surgery.

INTRODUCTION

The lesions of the carotid arteries are rare, although their incidence increases. The arterial aneurysm is defined as an increase in size of at least 50% of the expected caliber of the vessel, with loss of normal parietal symmetry [1]. However, this definition is poorly applied to aneurysms of the bulbar carotid segment, given the anatomical dilatation of the carotid artery; For this reason, the carotid aneurysm is defined as a dilatation of the bulb greater than 200% in relation to the diameter of the Internal Carotid Artery or greater than 150% of the diameter of the common carotid artery [2].

Sometimes these lesions reach particularly large dimensions (more than 70 mm), but these are, of course, exceptional cases [3]. The etiologies of false aneurysms are rare; it is often a bacterial infectious endocarditis, mycotic false aneurysms, penetrating trauma, iatrogenic causes (artery or vein puncture), and postoperative infections especially secondary to carotid endarterectomy [4].

We report a case of a common carotid aneurysm operated in the visceral surgery department of the Hubert Koutoukou Maga National University Hospital in Cotonou.

MEDICAL OBSERVATION

This is a patient of 26 years old, single without children admitted for the management of a false aneurysm of the left common carotid. The history of the disease recovers a beginning that dates back to about a year by the appearance of adenopathies under mandibular and mentally, motivating a consultation in a hospital center 400km from the capital after excision and pathological examination of a lymphadenopathy under mentally, the diagnosis of ganglionic tuberculosis

was retained and she was put on anti-tuberculosis treatment for 6 months, treated and declared cured.

The evolution under this treatment was marked two months later by the appearance of a mass in left lateral cervical region, painless, gradually increasing in volume, an ultrasound and a cervical scanner made it possible to conclude to an aneurysm of the carotid common left and She was referred to the CNHU for better care. She has been hypertensive for 2 months under beta-blocker (RETERSIAL) 5mg / day. Locally there was a mass, sitting in left lateral cervical region, about 8cm long axis and 4 cm short axis, flapping with a continuous systolic-diastolic murmur (Fig. 1).

The Doppler echo of the vessels of the neck revealed the appearance of a pseudoaneurysm of the left carotid carotid of (45) mm x 52.60 mm (Fig. 2). CT angiography of supra-aortic trunks revealed a left carotid aneurysm of 4.5 cm x 5 cm (Figure 4). Anatomico-pathological examination concluded with a histological aspect suggestive of a follicular follicular granuloma: ganglionic tuberculosis. Antituberculous treatment had led to clinical and laboratory

improvement with cervical lymph nodes disappearing but persistent carotid aneurysm.

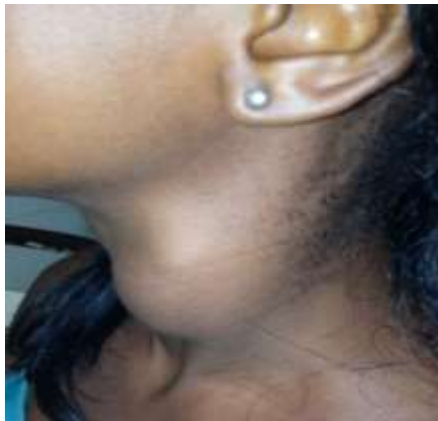

Fig-1: Physical aspect of the left lateral cerebral swelling (profile view photo)

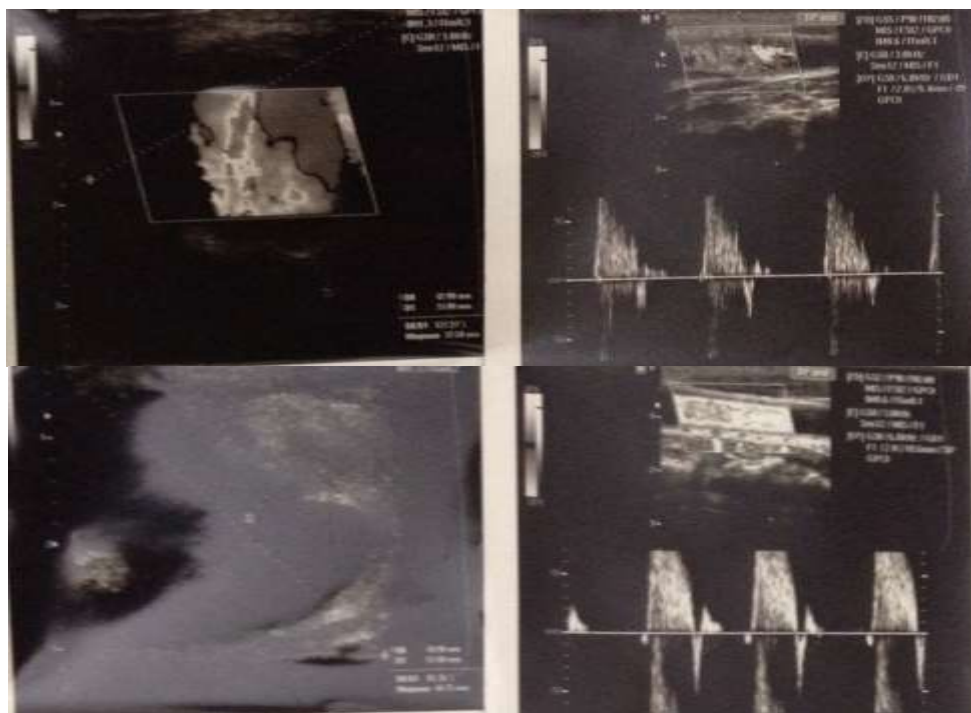


Fig-2: Ultrasound appearance of left cervical pseudoaneurysm

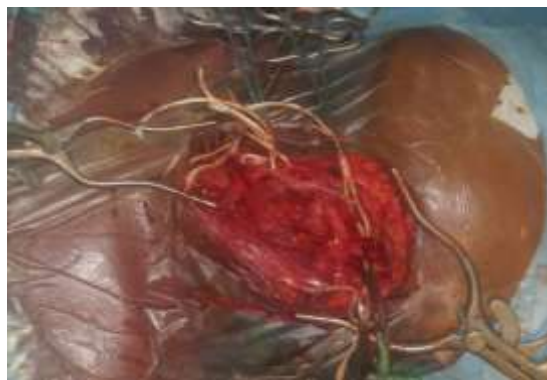

Fig-3: Intraoperative view of the surgical cure

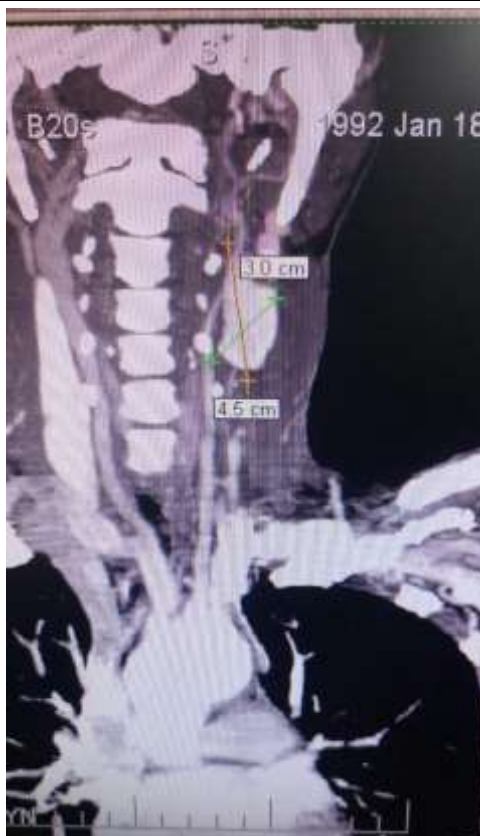

Fig-4: CT scan of the left cervical pseudoaneurysm

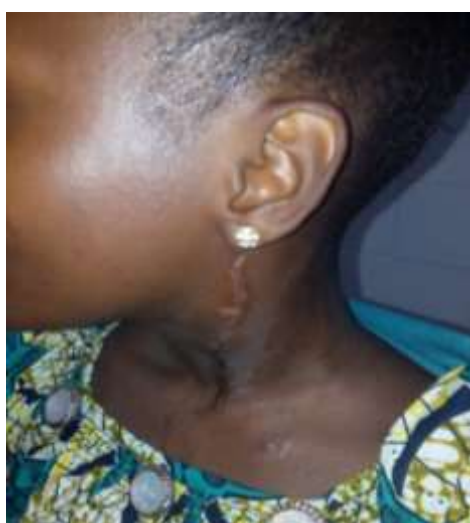

Fig-5: Post operative aspect

Under general anesthesia, the exploration found a false aneurysm of 6 cm x 5 cm at the expense of the common left common carotid. Resection of the pouch, emptying of the clots, debridement of the infected tissues and placement of a 1.5 cm diameter venous patch by two proline 5/0 hemi-sites. The postoperative course was simple. No anti-tuberculous treatment was administered

DISCUSSION

Carotid aneurysms are a rare event with an incidence of 0.5 to 1% in the surgical literature [5]; they

represent 3.6% of peripheral arterial aneurysms [6], 0.4 to 1% of all arterial aneurysms [7] and 0.1% to 2% of all carotid surgery [8,9].

The observation that we report is that of a 26-year-old patient, a young subject, contrary to data from the literature, who found an average age of discovery varying between 53 and 56 years [10, 11]. This could be explained by the infectious context of our patient because the etiologies of carotid aneurysms extra cranial are multiple.

Our patient first presented adenopathies under mandibular and mentally. She then presented a cervical tumefaction this poses the problem of the precocity of the infra-clinical diagnosis which should be helped by the imagery notably the arterial echo-Doppler and the angioscanner which were of great interest in our patient.

In general, carotid aneurysms or extra-cranial aneurysms are diagnosed in 83% of cases with central or peripheral neurological symptoms or with local symptoms (swelling, pain, compression of neighboring organs) [12]. However ectasia can be dumb and chance discovery. The positive diagnosis of carotid aneurysms is based on clinical examination. Doppler echo is the complementary exploration that we carry out with first intention. Arteriography has given way in recent years to other forms of arterial opacification and particularly to spiral CT angiography [13].

In the context of infectious diseases and the risks of rupture, thromboembolic complications and the results of conservative treatment, which exposes a high risk ranging from 16% to 100% of neurological events of thromboembolic origin [14], we opted for straight to conventional surgery. It consisted of debridement of the infected tissues to make a venous patch 1.5 cm in diameter because of the reduced size of the collar because one could have made an interposition of venous graft if the aneurysm involved a segment of the artery.

However, it is important to know that endovascular treatment is possible and has been reported in the literature and often in the form of clinical cases [15]. The short-term results of this treatment option appear to be satisfactory, but the long-term remains to be evaluated particularly in terms of permeability.

The evolution of surgical management is satisfactory with perioperative mortality is less than 6.1% and the stroke rate varies from 1.6% to 7.6% [9, 12]. Our patient did not have any complications with ultrasound control that did not show vascular lesions. She is currently in the third postoperative month but her follow-up remains regular because the late mortality is estimated at 14.6% after an average follow-up of eight years, 0.3% of the deaths were attributable to a stroke and 47.7% were secondary to myocardial infarction [12, 16]. The ischemic cerebral accidents occurred in 1.3% of the cases and are most often secondary to an anatomic degradation of the bypass [12, 16].

However, late mortality has significantly decreased since the shift from a palliative occlusive therapeutic attitude to a restorative one [16, 17, 18]. This rate, which is much lower than that observed in the natural history of these false aneurysms, bears witness to the indisputable benefit of the surgical cure.

CONCLUSION

Carotid aneurysms are rare with a natural evolution marked by complications. The diagnosis is made through clinical examination and paraclinical explorations (ultrasound and CT angiography).

Surgical treatment remains the reference treatment because it allows a morphological carotid reconstruction.

Conflicts of interest

The authors do not declare any conflict of interest.

REFERENCES

1. Johnston Kw, Rutherford Rb, Tilson Md, Shah Dm, Hollier L, Stanley Jc. Suggested standards for reporting on arterial aneurysm. *J Vasc Surg.* 1991;13(3) : 444-50.
2. De Jong Kp, Rutherford Rb, Tilson Md, Shah Dm, Hollier L, Stanley Jc. Suggested standards for reporting on arterial aneurysm. *Eur J Vasc Surg.* 1989;3(6) : 557-62.
3. Kawada T, Oki A, Iyano K, Bitou A, Okada Y, Matsuo Y, Aiba M, Yamada M, Michihata T, Inoue K, Takaba T. Surgical treatment of atherosclerotic and dysplastic aneurysms of the extracranial internal carotid artery. *Ann Thorac Cardiovasc Surg.* 2002;8(3) : 183-7.
4. Lee HY, Cho SH, Kim HS, Moon JM, Lee S, Kim JI. Non-Tuberculous Mycobacterium Induced Pseudoaneurysm of the Common Carotid Artery. *The Korean journal of thoracic and cardiovascular surgery.* 2016 Dec;49(6):468.
5. Srivastava SD, Eagleton MJ, O'Hara P, Kashyap VS, Sarac T, Clair D. Prise en charge chirurgicale des anévrysmes de l'artère carotide: Expérience monocentrique de dix ans. *In Annales de Chirurgie Vasculaire* 2010 Jan 1 (Vol. 24, No. 1, pp. 111-117). Elsevier Masson.
6. Lim YM, Lee SA, Kim DK, Kim GE. Aneurysm of the extracranial internal carotid artery presenting as the syndrome of glossopharyngeal pain and syncope. *Journal of Neurology, Neurosurgery & Psychiatry.* 2002 Jul 1;73(1):87-8.
7. Lipari G, Riva F, Muselli P, Armatura G, Lino M, Shamale A, Baggio E. Anévrysmes de l'artère carotide interne extra-crânienne: à propos de 2 cas. *Journal des maladies vasculaires.* 2006 Jul 1;31(3):152-8.
8. Castelli P, Scamoni C, Caronno R, Piffaretti G, Tozzi M, Carnini M. Giant aneurysm of the extracranial carotid artery. *EJVES Extra.* 2005; 9(4) : 84-86.
9. El-Sabrou R, Cooley DA. Extracranial carotid artery aneurysms: Texas Heart Institute experience. *Journal of vascular surgery.* 2000 Apr 1;31(4):702-12.

10. Bakoyiannis CN, Georgopoulos SE, Tsekouras NS, Klonaris CN, Skrapari IC, Papalambros EL, Bastounis EA. Surgical management of extracranial internal carotid aneurysms by cervical approach. ANZ journal of surgery. 2006 Jul;76(7):612-7.
11. Shyamkumar N, Varcoe R, Sebben R, Fitridge R. Endovascular management of double fusiform aneurysms of the extracranial internal carotid artery with covered stents Vasc Dis Manag. 2005 ; 2 : 102-104
12. Ouldsalek E, El Idrissi R, Elfatemi B, Zahdi O, Lekehal B, Sefiani Y, El Mesnaoui A, Bensaid Y. Un anévrisme de l'artère carotide interne d'origine dysplasique. Journal des Maladies Vasculaires. 2014 Dec 1;39(6):439-42.
13. Coffin O, Maiza D, Galateau-Sallé F, Martel B, Vignon C, Neri E. Résultats du traitement chirurgical des anévrismes de l'ACI par voie cervicale. Ann ChirVasc. 1997;11:482-90.
14. Szopinski P, Ciostek P, Kielar M, Myrcha P, Pleban E, Noszczyk W. A series of 15 patients with extracranial carotid artery aneurysms: surgical and endovascular treatment. European journal of vascular and endovascular surgery. 2005 Mar 1;29(3):256-61.
15. Kota AA, Sen I, Dheepak Selvaraj A, Premkumar P, Ponraj S, Agarwal S. Mycotic aneurysm case serie. Indian Journal of vascular and endovascular surgery, Jan-Mars. 2015; 2 (1): 38-40
16. Rosset E, Albertini JN, Magnan PE, Ede B, Thomassin JM, Branchereau A. Surgical treatment of extracranial internal carotid artery aneurysms. Journal of vascular surgery. 2000 Apr 1;31(4):713-23.
17. Alpogut U, Ugurlucan M, Kafali E, Sayin OA, Demir T, Basaran M, Demir HB, Dayioglu E, Onursal E. Aneurysm of the kinked extracranial internal carotid artery case report and review of the literature. Acta Chirurgica Belgica. 2005 Jan 1;105(4):407-9.
18. Kaouel K, Mechergui S, Mrad IB, Mrad MB, Ghédira F, Mizouni H, Omrane SB, Elleuch N, Denguir R, Kalfat T, Menif E. Traitement chirurgical des anévrismes carotidiens extracrâniens: à propos de dix cas. Journal des Maladies Vasculaires. 2012 Jul 1;37(4):201-6.