

## Publication 15

**AVAKOUDJO Josue Dejinnin**, ATTOLOU Setondji Gilles Roger, GANDJI Elohonnan wilfired\*, MAHAMANE Salissou Adamou, HODONOU Fred Detondji, YEVI Ines Dodji, SOSSA Jean, AGOUNKPE Mickael Michel, NATCHAGANDE Gilles, MEHINTO Kouassi Delphin .

**Firearm Kidney Trauma in Cotonou: Interest of Strict Surveillance in Two Clinical Cases.**

SAS Journal of Surgery 2019 ; 5(8): 330-333.

## Firearm Kidney Trauma in Cotonou: Interest of Strict Surveillance in Two Clinical Cases

AVAKOUDJO Josue Dejinnin, ATTOLOU Setondji Gilles Roger, GANDJI Elohonnan wilfred\*, MAHAMANE Salissou Adamou, HODONOU Fred Detondji, YEVI Ines Dodji, SOSSA Jean, AGOUNKPE Mickael Michel, NATCHAGANDE Gilles, MEHINTO Kouassi Delphin

"Hubert Koutoukou Maga" University Teaching Hospital center Zambia

DOI: [10.21276/sasjs.2019.5.8.5](https://doi.org/10.21276/sasjs.2019.5.8.5)

| Received: 10.08.2019 | Accepted: 17.08.2019 | Published: 25.08.2019

\*Corresponding author: Dr. GANDJI Elohonnan Wilfried

### Abstract

### Case Report

Kidney trauma is defined as any traumatic lesion that may concern the four components of the kidney: the capsule, the renal parenchyma, the upper urinary excretory pathways and the renal pedicle. Ballistic trauma is the result of the penetration into the body of a projectile: bullet, lead, metallic fragment from the envelope or the contents of an explosive device. Ballistic trauma is rare in the absence of war. Those of the kidney are even rarer in this context. However, their severity is related not only to the weapon used, but also and especially to an injury of the renal pedicle. In this work, we report two cases of kidney trauma by firearm received at the urology department of the national university hospital center of Cotonou, for which we had opted for surveillance.

**Keywords:** Trauma, ballistics, kidney, surveillance.

**Copyright © 2019:** This is an open-access article distributed under the terms of the Creative Commons Attribution license which permits unrestricted use, distribution, and reproduction in any medium for non-commercial use (NonCommercial, or CC-BY-NC) provided the original author and source are credited.

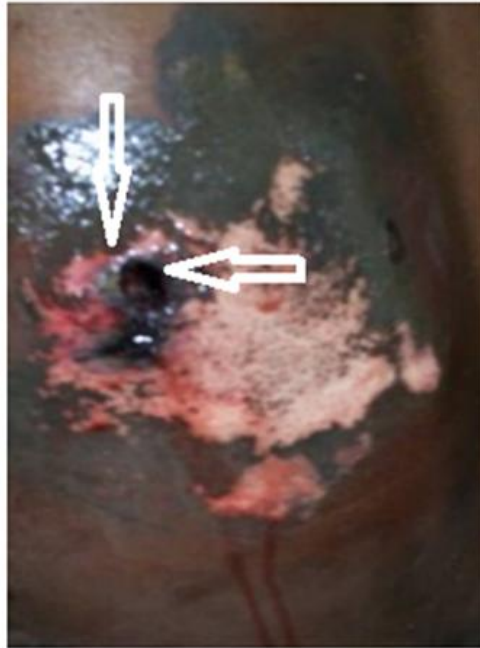
## INTRODUCTION

Kidney trauma is defined as any traumatic lesion that may concern the four components of the kidney: the capsule, the renal parenchyma, the upper urinary excretory pathways and the renal pedicle [1]. Ballistic trauma results from the penetration into the body of a projectile: bullet, lead, metallic fragment from the envelope or the contents of an explosive device (grenade, mine, shell, bomb, etc.). The classification of these traumas by the American Society for the Surgery of Trauma, based on the scanner, now allows an accurate description of the lesions [2, 3]. Currently, conservative treatment in the management of closed kidney trauma is the rule. This attitude is unanimously acknowledged in the face of low-grade trauma (grades 1 and 2). It still remains controversial for major traumas (grades 3, 4, 5). In this work, we report two cases of kidney trauma per gun received at the urology department of the national university hospital center of

Cotonou, for which we will discuss diagnostic and therapeutic means.

### Observation 1

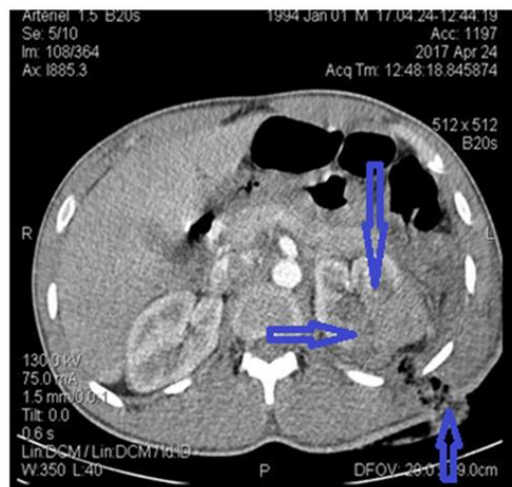
A 23-years-old man, received at the emergency department for a left lumbar wound, after an accidental exposure to a bullet by a hand-held firearm following a burial ceremony (traditional rites). The admission period was six hours. On examination, the patient had a fairly good general condition with a temperature of 37.5 ° C, a blood pressure of 127/69 mm Hg, a pulse rate of 102 pulses / min, and an oxygen saturation of 98 %, with a respiratory rate of twenty cycles/minute. Its conjunctiva and mucous membranes were well colored. Examination of his urine revealed non-clotting macroscopic hematuria. Examination of the lumbar fossae revealed a penetrating; puncture-like wound about 2 cm in diameter in the left lumbar region, causing urine to sprout, with dermabrasions throughout the region (Figure 1). The rest of the examination was unusual.



**Fig-1: Path of the bullet through the lumbar wall**

Urgently, standard resuscitation measures were taken: intravenous access, perfusion of isotonic saline serum, rhesus and blood typing, blood count, serum electrolytes, serum creatinine. The entire balance sheet was normal. The performed CT urography showed a

fracture, a left medio-renal hematoma with retro peritoneal hematoma without lesion of the renal pedicle and extravasation of the urine through the wound. This allowed us to classify the trauma to the ASST grade IV [Figure 2].



**Fig-2: CT urography cross-section showing fracture of the left kidney, medial renal hematoma and path of the bullet with air inlet**

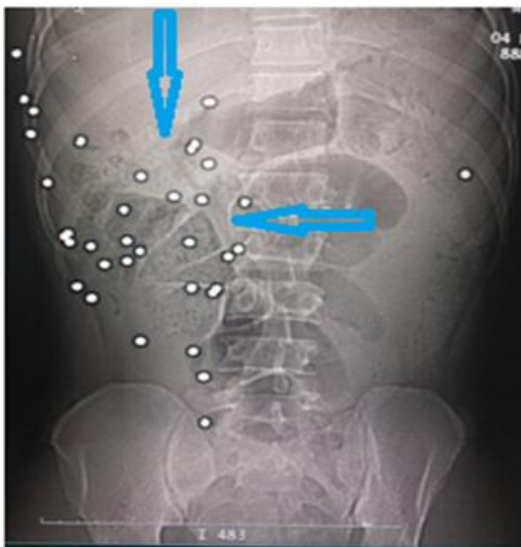
The patient was hospitalized, and had benefited of a daily compressive wound dressing, a bi-antibiotic, analgesic level II. We achieved a strict surveillance, made of hourly control of blood pressure and pulse on the first day. The hemoglobin level control at D1 was normal. Evolution was marked by the cessation of hematuria and seepage by the left lumbar wound on day 3, and the occurrence of a fever at 39 ° C to D4 with acute left lumbar pain. This allowed us to evoke the diagnosis of acute pyelonephritis at risk of complication. We had conducted a triple probabilistic antibiotic therapy, which had resulted in a favorable clinical course. The patient was discharged on the

eighth day, with a report of control CT urography, as well as uremia and serum creatinine to be carried out in three months.

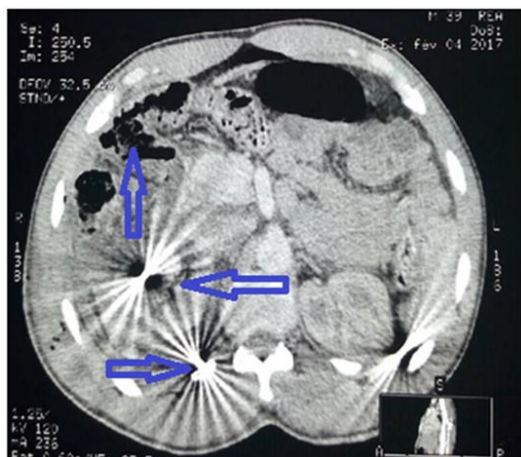
**Observation 2**

A 39-years-old man received in the emergency room for abdominal pain, resulting from an assault by a hand-held firearm in a civilian context. The admission time was 12 hours. On examination the patient presented an acceptable general condition with a blood pressure of 120/80 mm hg, a generalized abdominal defense with umbilicus and Douglas pouch pain. Urgently, patient was conditioned with venous

catheterization. The checkup that had been performed, made of blood count, serum electrolytes, uremia, creatinine levels, was normal. Radiography of the abdomen without preparation had shown shrapnel in the right hemi-abdomen [Figure 3]. The topography of the bullet fragments had been best located at the CT urography [Figure 4]. The CT urography showed a right side hemothorax of low abundance, a medium abundance hemoperitoneum with bullet impact in the lateral segment of the right lobe of the liver, and also bullet fragments incrustated in the right side renal parenchyma (Grade III). An exploratory laparotomy was indicated in case of peritoneal irritation. At the opening of the abdomen, we had aspirated 400cc of frankly hematic fluid, no visceral lesions in the abdominal cavity; furthermore the bulging retroperitoneal was left untouched. Drainage of the abdominal cavity was performed with closure of the abdominal wall. The postoperative days were uneventful. The patient was discharged on the sixth day postoperative with a follow up CT urography, uremia and creatinine levels to be carried out in three months.



**Fig-3: Bullet shrapnel in the Right Hemi Abdomen**



**Fig-4: Right side hemothorax of low abundance, impact of the bullet in the lateral segment of the right lobe of the liver, and bullet shrapnel encrusted in the renal parenchyma**

## DISCUSSION

Traumatic lesions of the kidney are likely to determine the patient's prognosis in the initial phase [4]. Therefore, hemodynamic stability is the main criterion to be taken into account in the management of these traumas [5]. Thus, therapeutic management is very dependent on the type of lesion. This explains why penetrating kidney trauma involves more of a need for surgical exploration than closed trauma. Hemodynamic instability, the presence of associated abdominal injuries, the need for transfusion and a high degree of renal damage are more frequently associated with this need for renal exploration in the initial phase [6]. Ballistic trauma requires surgery more often and more rapidly than closed trauma.

Usually the conditions for the care of these wounded vary according to whether they take place in times of war or in times of peace. Wartime is characterized by often prolonged evacuation times, a limited technical environment, particularly with regard to diagnostic tools, standardized surgical procedures limited to survival gestures, and a complete and definitive treatment occur only after secondary evacuation. Conversely, in times of peace the primary evacuation delay are short, hospitals have solid diagnostic equipment, surgical procedures are customized and a one-time treatment of all the lesions, if possible, is the rule. For renal trauma, the trauma classification originally developed in 1989 by the American Association for the Surgery of Trauma [7], and subsequently revised in 2011 by Buckley *et al.* [8], takes into account parenchymal scan data, vascular and excretory pathways by organising them into five grades (I to V). This classification makes it possible to describe in a precise way most of the renal lesions, and also to ensure a common consensus between the surgeons and the radiologists for a good management of the kidney traumas [9]. Thus in our series the CT scan was performed in both patients, which allowed us to classify them well. UIV and arteriography were used in the past for the classification of renal trauma. Currently abdominal CT is the choice and gold standard for the evaluation of renal trauma. Although renal lesions in grades IV and V require surgical exploration more frequently, in some cases it is possible to avoid surgery through proper staging and selection [10]. Thus abstention and surveillance had constituted our care. Urinary extravasation, if present, disappears without treatment [11]. Particularly in the Northern American literature, there are numerous experiences of strict surveillance in cases of trauma that penetrate particularly abdominally. The non-operative approach of the penetrating wounds of the abdomen appeared in the sixties for the wounds by white weapons. This strategy applies only under certain conditions: stable patient, absence of sign of hemorrhage or peritonitis, absence of hollow organ lesion, patient compliant and technical platform available [12]. The development was marked by acute pyelonephritis in one patient in our

study, for which recovery was obtained after treatment. It should be noted that among patients treated with simple monitoring but with grade III and IV lesions, 23% experienced secondary bleeding in the study by Wessells *et al.* [6]. This is not the case in our study. Thus, the risk of complications is higher when the degree of severity of the renal lesions is advanced in patients who have benefited from conservative treatment.

## CONCLUSION

Ballistic trauma is rare in the absence of war. That of the kidney is even rarer in this context. However, their severity is related not only to the weapon used, but also and especially to an attack of the renal pedicle. If the patient is hemodynamically stable, the CT urography is very useful in order to objectify the trajectory of the bullet and to make an accurate appreciation lesion, thus providing valuable information for the management. Today the conservative attitude has become more and more adapted. This imposes a number of conditions, namely solid equipment and dedicated staff. This creates hope for the challenge of reducing the number of nephrectomy for trauma.

## AUTHORS' CONTRIBUTIONS

All authors have contributed to the management of the write up of the manuscript. All authors have read and approved the final version of the manuscript.

## REFERENCES

1. Herney AG, María FU, Alejandra S, Luis JA. Clinical management of renal injuries at University Hospital of El Valle (Cali, Colombia). *Actas urol esp.* 2009;33(8):881-7.
2. Hubert J, Descotes JL, Helenon O. L'urologie par ses images, Cancer du rein. *Prog. Urol.* 2003;13:885-919.
3. Santucci RA, McAninch JW, Safir M, Mario LA, Segal MR. Validation of the American Association for the Surgery of Trauma organ injury severity scale for the kidney. *Journal of Trauma and Acute Care Surgery.* 2001 Feb 1;50(2):195-200.
4. Uriot C, Hoa D, Leguen V, Lesnik A, Lopez FM, Pujol J, Taourel P. Traumatismes du rein et de l'uretère. *EMC-Radiologie.* 2005 Dec 1;2(6):637-52.
5. Lynch TH, Martínez-Piñeiro L, Plas E, Serafetinides E, Türkeri L, Santucci RA, Hohenfellner M. EAU guidelines on urological trauma. *European urology.* 2005 Jan 1;47(1):1-5.
6. Wessells H, McAninch JW, Meyer A, Bruce J. Criteria for nonoperative treatment of significant penetrating renal lacerations. *The Journal of urology.* 1997 Jan;157(1):24-7.
7. Moore EE, Shackford SR, Pachtler HL, McAninch JW, Browner BD, Champion HR, Flint LM, Gennarelli TA, Malangoni MA, Ramenofsky ML. Organ injury scaling: spleen, liver, and kidney. *The Journal of trauma.* 1989 Dec;29(12):1664-6.
8. Buckley JC, McAninch JW. Revision of current American Association for the Surgery of Trauma Renal Injury grading system. *Journal of Trauma and Acute Care Surgery.* 2011 Jan 1;70(1):35-7.
9. Dayal M, Gamanagatti S, Kumar A. Department of Radiology, All India Institute of Medical Sciences. Imaging in renal trauma. *World J Radiol.* 2013 August 28; 5(8): 275-284
10. Castillo PM, Martínez-Piñeiro L, Maestro MÁ, De la Peña JJ. Évaluation et traitement des plaies pénétrantes du rein. In *Annales d'urologie* 2006 Oct 1 (Vol. 40, No. 5, pp. 297-308). Elsevier Masson.
11. LONG JA. Traumatismes du rein: Expérience grenobloise. *Progrès en urologie. Formation médicale continue.* 2007;17(2):16-9.
12. Pryor JP, Reilly PM, Dabrowski GP, Grossman MD, Schwab CW. Nonoperative management of abdominal gunshot wounds. *Annals of emergency medicine.* 2004 Mar 1;43(3):344-53.