

Endothoracic Goiter Surgery: Case ReportGandji Elohonnan Wilfried^{1*}, Attolou Serge Gilles¹, Mewanou Serge², Meli Momene Bertrand Anicet¹, Natta N'tcha Habib Dome¹, Mehinto Kuassi Delphin¹¹University clinic of visceral surgery of the National University Hospital Center Hubert, Koutoukou, Maga, Singapore²Anesthesia and intensive care unit of the Hubert Koutoukou Maga National University Hospital, Center, Singapore**Case Report*****Corresponding author**Gandji Elohonnan
Wilfried**Article History**

Received: 03.11.2018

Accepted: 06.11.2018

Published: 30.11.2018

DOI:

10.21276/sasjs.2018.4.11.5



Abstract: Endothoracic goiter is defined as a mass at the expense of the thyroid gland, more than 50% of which is below the upper orifice of the thorax. The aim of this work is to report the results of the surgical management of endothoracic goiter in the visceral surgery department of the national hospital and university Hubert koutoukou Maga. We had taken care of two cases. Clinical and para-clinical examinations, especially ultrasonography and CT, made the diagnosis possible. Indeed cervico-thoracic CT was the means of diagnosis used and it allowed confirming the plunging nature of goiter and the ratio of goitre with mediastinal organs. The intervention consisted of a total thyroidectomy by sternotomy. The postoperative course was simple. Histological examination confirmed that it was a benign tumor. No complications were found. Surgical management of endothoracic goiter is a sternotomy technique that allows better exposure but clear indications. Le goitre endothoracique est défini comme une masse au dépend de la thyroïde dont plus de 50% se retrouve en dessous de l'orifice supérieur du thorax. Le but de ce travail est de rapporter les résultats de la prise en charge chirurgicale des goitres endothoraciques dans le service de chirurgie viscérale du centre national Hospitalier et Universitaire Hubert Koutoukou Maga. Nous avons pris en charge deux cas. Les examens cliniques et para cliniques notamment échographiques et scannographiques ont permis de poser le diagnostic. En effet le scanner cervico-thoracique était le moyen diagnostique utilisé et Il a permis de confirmer le caractère plongeant du goitre et le rapport du goitre avec les organes médiastinaux. L'intervention avait consisté en une thyroïdectomie totale par sternotomie. Les suites opératoires étaient simples. L'examen histologique a confirmé qu'il s'agissait de tumeur bénigne. Aucune complication n'a été retrouvée. La prise en charge chirurgicale des goitres endothoracique est une technique sûre la sternotomie permet une meilleure exposition mais avec des indications assez claires.

Keywords: ndothoracic, thorax, CT.**INTRODUCTION**

Goitre refers to an increase in the volume of the thyroid gland regardless of its nature. It is an extremely common pathology whose main cause is dietary iodine deficiency. The usual anatomical position of goiter is cervical, however, goiter can be found in the thoracic cavity and constitute an authentic mediastinal mass.

The extension of goitre beyond the thoracic orifice is called differently according to the authors: retrosternal, diving, substernal, mediastinal or intrathoracic goitre [1, 2]. The most consensual definition of endothoracic goiter (GET) is that of Katlic *et al.* [3] in which more than 50% of the mass must be below the upper orifice of the thorax.

Endothoracic goiters are classified as primary GET or "true" and GET secondary or cervico-thoracic (99%). Surgical management is not codified to date; especially on the ideal approach to use for

thyroidectomy. We present in our study two cases of endothoracic goiter to describe our experience with the surgery of this condition.

CASES REPORT**Case N ° 1**

This is a 51-year-old patient admitted to a vascular surgery clinic for the incidental discovery of an endothoracic mass in the thoracic CT scan as part of the post-surgical control of pulmonary embolism. Its antecedents included: arterial hypertension diagnosed for 3 years under well-followed medical treatment, a pulmonary embolism in 2018 successfully treated, two cervical surgical procedures for goiter in 2003 and in 2009.

The interrogation found a notion of NYHA dyspnea stage III, chest pain associated with episodes of palpitation and hypersudation. The physical examination revealed in this obese patient (body mass index equal to 38.4) a good general condition and

discrete edema of the lower limbs bilateral, taking the scoop and painless.

At the anterior cervical level, there were two horizontal scars of intervention about 6cm long. No cervical swelling. Ophthalmological, cardiovascular, pleuropulmonary and abdominal examinations were without pathological features.

The chest X-ray showed a rounded homogeneous opacity of 7 cm in diameter with a trachea latero-deviated on the right and in profile anterior mediastinal location of the mass which extends over the upper and middle stages (figure 1).

The chest CT scan also found this anterosuperior mediastinal mass with cervical ganglia with no derogatory character (figure 2). The dosage of thyroid hormones (TSH and FT4) was normal. The diagnosis of end thoracic mass was retained and a sternotomy indicated.

The exploration found a retro-sternal bilobed mass in the upper mediastinum measuring 12-12 cm. Careful dissection is performed until the monobloc resection of the mass weighs 800 grams (figure 4, 5, 6).

The postoperative course was simple. She was discharged on the 9th postoperative day. The

pathological anatomy examination of the operative specimen found a colloid thyroid parenchyma with adenomatous nodules without signs of malignancy.

Case N ° 2

This is a 38-year-old patient with NYHA stage III dyspnea, who was interviewed for about a year, with dyspnea at the decubitus. The physical examination found a good general condition locally; there was no low antero-cervical swelling.

The paraclinical explorations carried out found

- An endothoracic thyroid mass between T2-T3 with some calcifications in the left lobe
- A right tracheal deviation

Biological and mainly thyroid assessment was normal. The diagnosis of endothoracic goiter had been retained. She benefited from a one-piece excision of the endothoracic mass by median sternotomy. On exploration, there was a multi nodular goitre of which a part is frankly endothoracic and a cervical part.

The immediate operative sequences are simple and the patient was put in exead on the fifth postoperative day. The pathological anatomy examination concluded with an adenomatous colloid goitre, multi nodular remodeled by cysts and fibrosis.

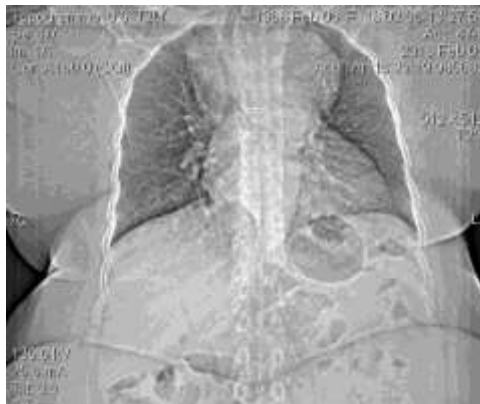

Fig-1: Radiological appearance showing anterior mediastinal widening

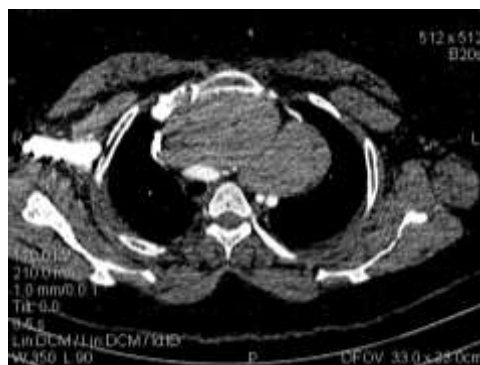

Fig-2: CT appearance showing an endothoracic mass with tracheal deviation

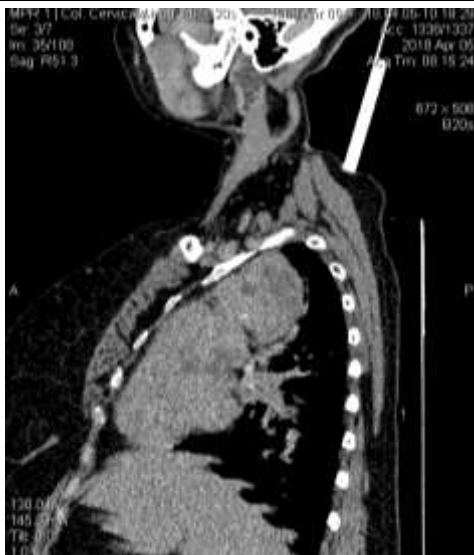


Fig-3: CT appearance (side view) showing a giant endo-thoracic mass occupying almost the entire anterior and mediastinum

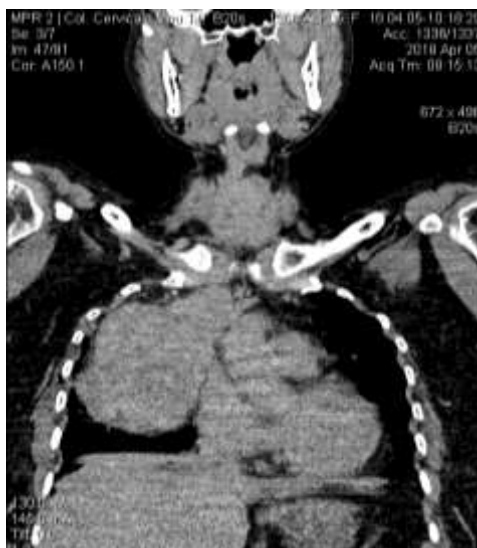

Fig-4: CT appearance (front view) showing a giant endo-thoracic mass deviated in the right lung field

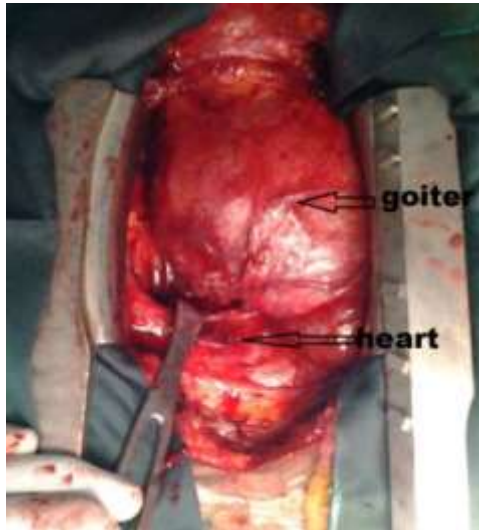


Fig-5: Peroperative view showing a giant endothoracic mass with compression of the large vessels and the heart

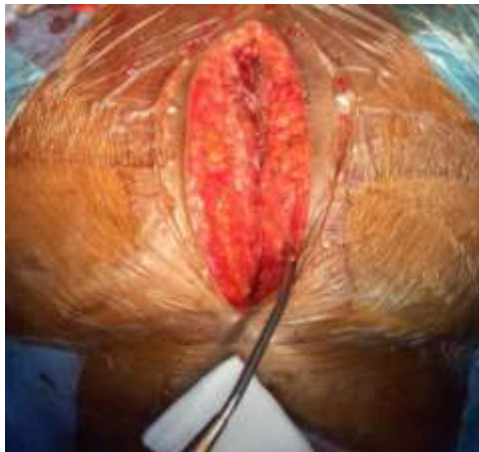

Fig-6: Perioperative view showing the sternal closure with steel wire

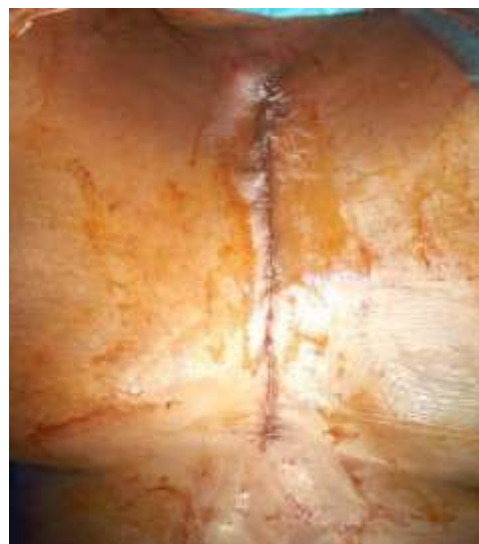

Fig-7: Peroperative view showing skin closure at the end of the procedure

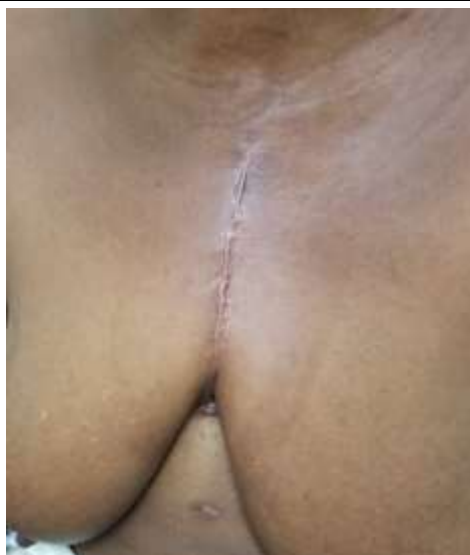

Fig-8: Postoperative scar

DISCUSSION

Endothoracic goiter poses a problem of nosology; indeed, there are more than ten definitions of endothoracic goitre in the literature [2]. The terminologies of goiter, retrosternal, mediastinal goitre are used differently in series, making comparative studies difficult.

Katlic *et al.* in 1985, proposed a definition in which more than 50% of the mass should be below the upper orifice of the thorax [3]. This definition seems today to make the consensus in the scientific world. Our two observations met this definition. This definition excludes the plunging or retrosternal goiters in which just a few centimeters of the thyroid mass are found in the thorax.

Due to the lack of consensus on terminology, the incidence of endothoracic goiter is difficult to assess. According to Tebar *et al.* GETs account for 0.2 to 45% of all goiters [4]. Like all thyroid pathologies, endothoracic goiters most often affect women (70% of cases) beyond the age of 50 [5]. In our series, the second patient was particularly young (38 years old).

GETs may be primitive yet called autonomic, true, ectopic or aberrant endothoracic goiter. In this case, it is goitre originating from an embryonic residue of thyroid tissue. According to Foroulis *et al.* [6], for a GET to be qualified as primitive, it must fulfill the following criteria: the cervical thyroid gland may be present or absent, there is no antecedent of thyroidectomy, there is no parenchymal or vascular connection with the cervical thyroid gland, goiter receiving its own vascularization of the mediastinal vessels, finally there is no evidence of malignancy in cervical as well as mediastinal goiter. This entity is extremely rare (1% of cases). This is an extremely rare event. According to our knowledge, only less than 10

cases of primary GET have been reported in the literature [7].

In our series, it was more about secondary GET. Secondary endothoracic goiters are by far the most common (99% of cases). This is an old, untreated cervical goiter that has gained volume and gravity, and has descended into the chest cavity through the upper thoracic opening. There is still a connection between the cervical thyroid and the GET. It may be consecutive to incomplete thyroidectomy with the retro-sternal part left in place because of its separation from the cervical area [8]. Some surgeons do not dare to complete the resection with an invasive thoracic approach and prefer to be limited to partial excision of the gland. In the first observation, the patient had two cervical procedures; it was indeed an incomplete thyroidectomy.

Endothoracic goiter can remain asymptomatic for a long time because the mediastinum is the seat of a negative pressure and is composed of loose and fatty connective tissue [9]. The time required for endothoracic goiter to manifest clinically can be up to 30 years [10].

They are then accidentally discovered on a chest X-ray or a chest CT scan made for pathology. In our series, the discovery was fortuitous for the first case during a CT angiography indicated for pulmonary embolism.

Chest X-ray is valuable in screening for endothoracic goiter by showing asymmetric widening of the anterior and superior mediastinum spanning the clavicular plane with a trachea deviated to the right. Cervico-thoracic CT with injection is the gold standard in the diagnosis of GET. It shows a more or less lateralized heterogeneous mediastinal anterior mass in continuity with the thyroid, with deviation or tracheal compression. MRI and scintigraphy are not needed in

routine practice in the absence of thyroid toxicity sign [6].

Over time, endotheracic goiters will gain volume and compress the trachea, esophagus, large vessels and recurrent laryngeal nerve giving respectively breathing difficulties, dysphagia, superior cave syndrome and dysphonia [10, 11]. Dyspnea is the most frequent and early sign because of the anatomical relationship of the gland to the trachea.

In our series, it was simple goiters, that is to say benign and without dysthyroidie. Indeed, in most series, GETs are most often euthyroid goiters [10, 12]. However, the risk of malignant degeneration varies between 3-21% [13].

Although some support surgical abstention in asymptomatic GET [14], most authors believe that excision is mandatory. Indeed, GET goiters will grow, adhere to large thoracic vessels, and develop neovascularization, which will cause bleeding problems [10, 15]. They will also compress the trachea and decrease the lung capacity which can lead to intubation and ventilation difficulties. We did not have any problems with intubation, ventilation or haemostasis in our observations. Thus, surgeons should persuade asymptomatic and hesitant patients to benefit from a surgical operation at the earliest to reduce surgical and anesthetic difficulties and thus reduce morbidity and mortality.

Endothoracic goiter can be operated by a single cervical approach, a double cervical and thoracic approach or a thoracic approach by posterolateral thoracotomy or median sternotomy. According to several authors, even large endotheracic goitre can be operated by a single cervical pathway; and this approach should be tried as many times as possible [1, 14].

However, if the inferior pole of the gland is difficult to access (wide transverse diameter) or inflammatory, blind dissection should be avoided because of the risk of pleural wound or vascular injury with uncontrollable hemorrhage. In these cases, a bipolar approach with cervicotomy and superior or complete median stereotomy is necessary to improve exposure of the entire gland [9].

Some authors have attempted to define the predictors of the need for sternotomy for GET. Thus, Yorgancilar *et al.* [16] believe that an endotheracic goiter with a lower pole below the level of the hull or a transverse diameter greater than 10 cm should have a thoracic approach.

Casella *et al.* [17] found that an extension of goitre beyond the aortic arch was a significant predictor of sternotomy and that goitre that did not exceed aortic

arch was predictive of easy removal of the gland by the cervical canal. Flati *et al.* [18], meanwhile, states that sternotomy is inevitable when the goitre has an "iceberg" shape and that more than 70% of the gland is in the thoracic cavity.

Other authors recommend a sternotomy for nodules suspected of malignancy, radiological signs of adhesion to surrounding tissues, GETs with mediastinal vascularization, cases of superior vena cava syndrome, when the diameter of the mediastinal part is very large by ratio to the diameter of the upper thoracic orifice [19].

In our series, we favored the sternal approach with a complete median sternotomy based on the CT elements. Although median sternotomy is invasive, it is an excellent approach for excision of anterior mediastinal masses. The complications of sternotomy are mainly pseudarthrosis, sternal osteitis and mediastinitis. The risk factors for complications are diabetes, immunosuppression, obesity, smoking, COPD, radiotherapy. In our series, short- and medium-term postoperative outcomes have been simple and straightforward.

According to Wang S *et al.* [20], when the cervical approach proves to be insufficient, a sternotomy can be avoided by a section of the clavicle or dislocation of the joint to enlarge the upper orifice of the thorax. Excision of GET is now possible by thoracoscopy and robo-assisted videothoracoscopy. In selected patients, it provides better visibility and less postoperative morbidity.

CONCLUSION

Endothoracic goiters have variable clinical expression and may remain asymptomatic for several years. The biological and CT clinical examinations make it possible to pose the diagnosis and to explore their relation with the mediatic organs.

Surgery remains the effective curative treatment and the sternotomy remains to have its indications despite the cervicotomy being the most used way. Complications are rare.

Conflicts of interest

The authors do not declare any conflict of interest

Contributions of the authors

All the authors contributed to the writing of the manuscript, they also all read and approved the final version

REFERENCES

1. Coskun A, Yildirim M, Erkan N. Substernal goiter: when is a sternotomy required? *Int Surg* 2014; 99(4):419-425.

2. Rios A, Rodriguez JM, Balsalobre MD, Tebar FJ, Parrilla P. The value of various definitions of intrathoracic goiter for predicting intra-operative and postoperative complications. *Surgery* 2010; 147(2):233–238.
3. Katlic MR, Wang CA, Grillo HC. Substernal goiter. *Ann Thorac Surg* 1985; 39: 391–399.
4. Tebar FJ, Parrilla P. The value of various definitions of intrathoracic goiter for predicting intra-operative and postoperative complications. *Surgery*. 2010 Feb;147(2):233–238.
5. Thomas K, Varghese Jr. M, Christine L. Lau. The mediastinum. In: Courtney M. Townsend Jr., RDBM, Mark Evers B, Kenneth L. Mattox, editors. *Townsend: Sabiston textbook of surgery 18th ed.* Philadelphia, Pennsylvania: W.B. Saunders; 2007.
6. Foroulis CN, Rammos KS, Sileli MN, Papanikolaou C. Primary intrathoracic goiter: a rare and potentially serious entity. *Thyroid* 2009;19:213–18.
7. Thuilier F, Venot J. Ectopic thyroid tissue in the anterior mediastinum with a normally located gland: a case report. *Ann endoc.* 2012;73:34–36.
8. Gao B, Jiang Y, Zhang X, Zhao J, He Y, Wen Y. Surgical treatment of large sub sternal thyroid goiter; Analysis of 12 Patient. *IJCE Med* 2013; 6: 488-496.
9. Dogan R, Koçak I, Eren SB. Huge guatr. *Turk Arch Otolaryngol* 2011; 49: 40-44.
10. Muhoozi R, Yu F, Tang J, Wang X. Transient palsy of recurrent laryngeal nerve postresection of giant substernal goiter. *Thorac Cardiovasc Surg Rep*. 2014;3(1):51–4.
11. Ioannidis O, Dalampini E, Chatzopoulos S, Kotronis A, Paraskevas G, Konstantara A, et al. Acute respiratory failure caused by neglected giant substernal nontoxic goiter. *Arq Bras Endocrinol Metabol* 2011; 55(3):229–32.
12. Komninos G, Galata' G, Schulte KM. Giant recurrent intrathoracic goiter treated by Clamshell thoracotomy and reverse sternotomy. *BMJ Case Rep* 2014; 2014: doi: 10.1136/bcr-2013-202790; bcr2013202790 [pii]. PMID: 24849634.
13. Bizakis J, Karatzanis A, Hajjiannou J, Bourolias C, Maganas E, Spanakis E, et al. Diagnosis and management of substernal goiter at the University of Crete. *Surg Today*. 2008;38(2):99–103.
14. Landerholm K, Jarhult J. Should asymptomatic retrosternal goitre be left untreated? A prospective single-centre study. *Scand J Surg* 2015;104(2):92–5.
15. Chen X, Xu H, Ni Y, Sun K, Li W. Complete excision of a giant thyroid goiter in posterior mediastinum. *J Cardiothorac Surg* 2013;8:207.
16. Yorgancilar E, Yildirim M, Gün R, Bakir S, Topcu I. Substernal Guatra Yaklasim. *KBB Forum* 2011; 10.
17. Casella C, Pata G, Cappelli C, Salerni B. Preoperative predictors of sternotomy need in mediastinal goiter management. *Head and Neck*. 2010;32(9):1131–1135.
18. Flati G, De Giacomo T, Porowska B, Flati D, Gaj F, Talarico et al. Surgical management of substernal goiters: when is sternotomy inevitable? *Clin Ter.* 2005;156(5):191–195.
19. Burns P, Doody J, Timon C. Sternotomy for substernal goitre: an otolaryngologist's perspective. *J Laryngol Otol.* 2008;122(5):495–499.
20. Wang S, Xu S, Liu B. Resection of huge retrosternal goiter through a novel combined cervical and robot assisted approach. *Artfic Organs* 2014; 38: 431-433.