



Case report

Laparoscopic management of a left hepatic vein injury during one -step laparoscopic Roux-en-Y gastric bypass after adjustable gastric banding removal: A case report

Ismail Lawani^{a,b,*}, Federico Costantino^b, Yacoubou Imorou Souaibou^a, Umber Morelli^b, Francis Moïse Dossou^a, Philippe Keller^b

^a Department of Surgery and Surgical Specialties, Faculty of Health Sciences, University of Abomey-Calavi, Benin

^b Department of General Digestive and Thoracic Surgery, Hôpital Pasteur, Colmar, France

ARTICLE INFO

Keywords:

Hepatic vein injury
Laparoscopic adjustable gastric band
Intraoperative vascular complications
Laparoscopic Roux en Y gastric bypass
Case report

ABSTRACT

Introduction and importance: The occurrence of a left hepatic vein injury during laparoscopic removal of an adjustable gastric band is exceptional and should be known by any surgeon approaching the hiatal region. We report here the laparoscopic control of such a wound.

Case presentation: A 39-year-old morbidly obese woman (body mass index 47.7 kg/m²) presented the failure in weight loss following a laparoscopic adjustable gastric banding. It was decided to perform a one-step laparoscopic Roux-en-Y gastric bypass. Laparoscopic exploration showed post-surgical tissular retraction and adhesions. After the lap-band™ removal the left hepatic vein was accidentally bluntly injured while freeing adhesions between left hepatic lobe and the stomach. After a direct hemorrhagic control, intraoperative diagnosis of left hepatic vein injury was confirmed. A laparoscopic repair was performed by two running sutures using absorbable monofilament 4/0. Then, a Roux-en-Y gastric bypass was performed without any other complications. Operative time was 119 min; intraoperative blood loss was estimated as 200 cm³. No blood transfusion was necessary. The total hospital stay was 48 h. The excess weight lost after 10 years was 87,9%.

Clinical discussion: Adjustable gastric band can modify anatomic landmarks, leading to a wrong dissection path, with possibility of left hepatic vein injury.

Conclusion: The left hepatic vein injury can occur during revisional surgery for laparoscopic adjustable gastric banding failure. Its laparoscopic management can be done safely, in trained hands without increasing morbidity.

1. Introduction

Obesity is a health problem affecting a considerable number of persons around the world, generating important social, physical and psychological consequences. Nutritional counselling and oral medication failed to achieved durable weight loss. Bariatric surgery is the only treatment that produces persistent long-term weight loss [1]. Multiples surgical, restrictive or malabsorptions approaches can be applied [2]. Laparoscopic adjustable gastric banding (LAGB) is one of the most popular bariatric restrictif procedure employed, and long-terms results of weight loss are well documented [3], but this procedure is also affected by a high percentage of failure [4] and require a revisional surgery [5]. Intraoperative major blood vessel injury during LAGB revisional surgery is uncommon [6] and can be lethal if they are not well

managed. We report this case for its extremely rare occurrence and to emphasize the role of acute surgical strategy to successfully control that complication trough a laparoscopic approach, in a tertiary and bariatric surgery hospital.

2. Presentation of case

This work has been reported in line with the SCARE 2020 criteria [7]. A 39-year-old morbidly obese woman (body mass index 47,7 kg/m², weight 122 kg, height 1.60 m) presented to our unit because of the failure in weight loss following a laparoscopic adjustable gastric banding Lap-Band™ performed at another hospital (only 6% loss of excess weight was achieved in 5 years after the implant). After a thorough preoperative evaluation that included chest radiography, barium

* Corresponding author at: 081BP7073 Tri Postal Aéroport, Cotonou, Benin.
E-mail address: ismaillawani@gmail.com (I. Lawani).

<https://doi.org/10.1016/j.ijscr.2022.107043>

Received 9 February 2022; Received in revised form 3 April 2022; Accepted 3 April 2022

Available online 6 April 2022

2210-2612/© 2022 The Authors. Published by Elsevier Ltd on behalf of IJS Publishing Group Ltd. This is an open access article under the CC BY-NC-ND license (<http://creativecommons.org/licenses/by-nc-nd/4.0/>).

swallow, upper GI endoscopy and routine psychological counselling, it was decided to remove the Lap-Band™ and to perform a laparoscopic Roux en Y gastric bypass. The procedure has been performed by a bariatric surgeon, with over 10 years of experience in laparoscopic bariatric surgery. He has a high volume of bariatric surgery.

Laparoscopic exploration showed the presence of post-surgical tissular retraction and strong adhesions in the esophago-gastric junction due to the previous surgical procedure. Once proceeded to the blunt and sharp removal of the adhesions, the Lap-Band™ was removed. The laparoscopic procedure continued by making an opening of small omentum while freeing adhesions between left hepatic lobe and the stomach. At this point, the left hepatic vein was accidentally bluntly injured by the instrument (Fig. 1).

A direct and effective hemorrhagic control was achieved by application of atraumatic grasper at the edges of the vascular lesion, in order to stop the active bleeding; this maneuver allows the surgeon to obtain effective control of the intra-abdominal bleeding and make a real topographic diagnosis of the lesion allowing an evaluation for further laparoscopic repair.

The vascular control achieved allowed to distinguish the different landmarks (the superior edge of the left liver, lesser curvature and the caudate lobe of the liver). At this moment the path of the inferior vena cava can be appreciated and followed. An intraoperative diagnosis of left hepatic vein injury was confirmed at this time.

A laparoscopic repair of the defect was adopted as surgical strategy. Two running sutures using absorbable monofilament 4/0 were used to close the vascular breach (Fig. 2). The operative video showing the steps of the laparoscopic management can be found at the following youtube URL <https://youtu.be/G9pb2qjHldk>. Once the vascular damage was repaired and hemostasis was completed, the surgical procedure continued realizing a laparoscopic Roux en Y gastric bypass without any other perioperative complications.

Operative time was 119 min, neither abdominal drain nor nasogastric tube was placed; intraoperative blood loss was estimated as 200 cm³. The patient was informed of the incident postoperatively. She was very satisfied that the surgeon was able to repair the vascular wound without converting to laparotomy. There were no complications or adverse outcomes. No blood transfusion was necessary. Liquid oral intake was started 4 h after surgery. Patients were discharged home on postoperative 48 h. The excess weight lost after 10 years was 87,9%.

3. Discussion

Additional surgery after laparoscopic adjustable gastric banding (LAGB) failure seems to be a logic option, and laparoscopic Roux-en-Y gastric bypass (LRYGB) currently remains one of the rescue options

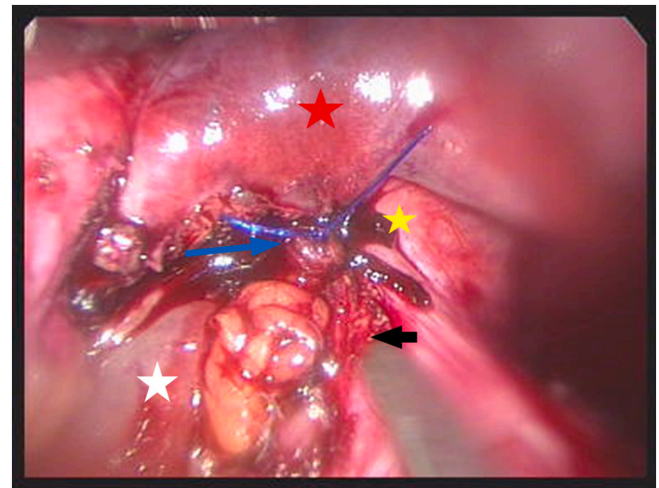


Fig. 2. Hemorrhagic control by sutures (blue arrow = sutures in place; black arrow = lesser curvature; red star = left liver; yellow star = esophagus; white star = caudate lobe). (For interpretation of the references to colour in this figure legend, the reader is referred to the web version of this article.)

with satisfactory results and acceptable morbidity [8]. It is called a revisional surgery, and performed in more than 20% of patients after laparoscopic gastric banding [9]. One-step revision is safe and feasible when a proper patient selection is done [5] in a specialized institution. Laparoscopic bariatric surgery is complex and technically demanding, especially LRYGB that include a long learning curve [10]. The technical challenge of the LAGB revisional surgery seems to be linked to the chronic inflammatory changes induced by the adjustable gastric band [11]. Typical anatomic landmarks are often extremely altered, leading to a wrong dissection path, with possibility of various iatrogenic injuries. Our case report shows the management of an uncommon and potentially fatal intraoperative injury of left hepatic vein during gastric band removal. This type of intraoperative complication arises during the dissection of retracted and fibrous tissue due to the tissular reaction to the band's material [11]. Surgeons having a strong experience in laparoscopy surgery can quickly manage this iatrogenic injury avoiding conversion to open surgery, preserving the minimally invasive purpose of this intervention. Laparoscopic management of vascular injuries is accomplished following the same principles of vascular control used in open operations [12]. After immediate recognition of injury, the surgeons should perform a rapid control via direct pressure, placement of extra port or ports if necessary, further mobilization and exposure of the vessel, reassessment of the injury, and repair of injury utilizing

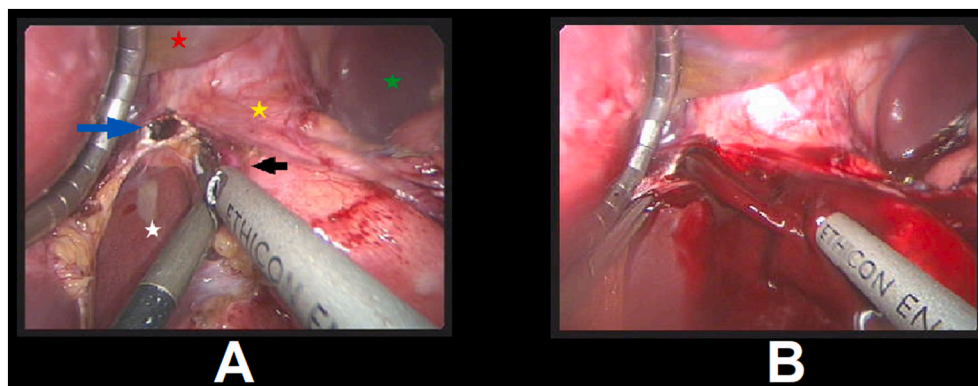


Fig. 1. Laparoscopic view of the left hepatic vein wound A) before bleeding, B) during bleeding (blue arrow = left hepatic vein wound; black arrow = lesser curvature; red star = left liver; yellow star = esophagus; green star = spleen, white star = caudate lobe). (For interpretation of the references to colour in this figure legend, the reader is referred to the web version of this article.)

laparoscopic technique or open conversion [12]. In our case, the rapid vascular control was achieved by application of atraumatic grasper at the edges of the vascular lesion, and allows quick diagnosis, good operative field exposure and saves time in order to choose the right strategy. This technical tip can help other laparoscopic surgeons to have another technic in case of bleeding arising from the left hepatic vein. Conversion into open surgery to achieve bleeding control is always another surgical option [13], but this involves time consuming laparotomy and risk of mayor blood loss. With a quick application of atraumatic grasps closing the vascular wound, the skilled laparoscopic surgeon can attempt a vascular repair without converting, bearing in mind that if minimal risk for patient safety or technical feasibility arisen, the conversion must be immediate. A ligation of left hepatic vein has been tested with dogs by Payne [14], it does not cause severe or permanent liver damage.

4. Conclusion

The left hepatic vein injury can occur during one-step LRYGB for Failed Gastric Banding. Its management can be done laparoscopically, in trained hands without increasing morbidity.

Sources of funding

This research did not receive any specific grant from funding agencies in the public, commercial, or not-for-profit sectors.

Ethical approval

Not applicable.

Consent

Written informed consent was obtained from the patient for publication of this case report and accompanying images. A copy of the written consent is available for review by the Editor-in-Chief of this journal on request.

Author contribution

Ismail Lawani and Philippe Keller: operation of the patient.

Ismail Lawani, Federico Costantino and Philippe Keller: Writing and original draft preparation.

Ismail Lawani, Federico Costantino, Philippe Keller, Yacoubou Imorou Souaibou, Umber Morelli and Francis Moïse Dossou: manuscript reviewer.

All the authors read and approved the final manuscript.

Registration of research studies

Not applicable.

Guarantor

The Guarantor who is responsible for the present case report is Ismail Lawani.

Provenance and peer review

Not commissioned, externally peer-reviewed.

Declaration of competing interest

The authors declare that they have no known competing financial interests or personal relationships that could have appeared to influence the work reported in this paper.

References

- [1] B.M. Wolfe, E. Kvach, R.H. Eckel, Treatment of obesity: weight loss and bariatric surgery, *Circ. Res.* 118 (2016) 1844–1855, <https://doi.org/10.1161/CIRCRESAHA.116.307591>.
- [2] Barrera RJO, Metabolic and bariatric surgery: evolution, techniques, and management, in: V. Neri (Ed.), *Gastrointest. Surg. - New Tech. Propos*, InTech, 2018, <https://doi.org/10.5772/intechopen.73676>.
- [3] J. Khoraki, M.G. Moraes, A.P.F. Neto, L.M. Funk, J.A. Greenberg, G.M. Campos, Long-term outcomes of laparoscopic adjustable gastric banding, *Am. J. Surg.* 215 (2018) 97–103, <https://doi.org/10.1016/j.amjsurg.2017.06.027>.
- [4] A. Brancatisano, S. Wahlroos, R. Brancatisano, Improvement in comorbid illness after placement of the Swedish adjustable gastric band, *Surg. Obes. Relat. Dis.* 4 (2008) S39–S46.
- [5] H. Alratrout, A. Almuttawa, I. Siciliano, P. Keller, Laparoscopic Roux-en-Y gastric bypass for failed gastric banding: one-step or two-step revisional surgery? *Obes. Surg.* 31 (2021) 646–653, <https://doi.org/10.1007/s11695-020-05027-9>.
- [6] A.J. Greenstein, A.S. Wahed, A. Adeniji, A.P. Courcoulas, G. Dakin, D.R. Flum, et al., Prevalence of adverse intraoperative events during obesity surgery and their sequelae, *J. Am. Coll. Surg.* 215 (2012) 271–277.e3, <https://doi.org/10.1016/j.jamcollsurg.2012.03.008>.
- [7] R.A. Agha, T. Franchi, C. Sohrabi, G. Mathew, A. Kerwan, A. Thoma, et al., The SCARE 2020 guideline: updating consensus Surgical CAse REport (SCARE) guidelines, *Int. J. Surg.* 84 (2020) 226–230, <https://doi.org/10.1016/j.ijsu.2020.10.034>.
- [8] A. Al-Kurd, R. Grinbaum, A. Abubeih, B. Siam, M. Ghanem, H. Mazeh, et al., Conversion of laparoscopic adjustable gastric banding to gastric bypass: a comparison to primary gastric bypass, *Obes. Surg.* 28 (2018) 1519–1525, <https://doi.org/10.1007/s11695-017-3047-1>.
- [9] M. Bueter, A. Thalheimer, A. Wierlemann, M. Fein, Reoperations after gastric banding: replacement or alternative procedures? *Surg. Endosc.* 23 (2009) 334–340, <https://doi.org/10.1007/s00464-008-9926-8>.
- [10] M. Lublin, S. Lyass, B. Lahmann, S.A. Cunneen, T.M. Khalili, J.D. Elashoff, et al., Leveling the learning curve for laparoscopic bariatric surgery, *Surg. Endosc.* 19 (2005) 845–848, <https://doi.org/10.1007/s00464-004-8201-x>.
- [11] N.J. Switzer, S. Karmali, R.S. Gill, V. Sherman, Revisional bariatric surgery, *Surg. Clin. North Am.* 96 (2016) 827–842, <https://doi.org/10.1016/j.suc.2016.03.004>.
- [12] M.D. Jafari, A. Pigazzi, Techniques for laparoscopic repair of major intraoperative vascular injury: case reports and review of literature, *Surg. Endosc.* 27 (2013) 3021–3027, <https://doi.org/10.1007/s00464-013-2845-3>.
- [13] A. Mechchat, P. Bagan, Management of major vascular complications of laparoscopic surgery, *J. Visc. Surg.* 147 (2010) e145–e153, <https://doi.org/10.1016/j.jvisc.2010.08.002>.
- [14] J.T. Payne, R.A. Martin, M.L. Moon, G.K. Saunders, L. Donaldson, M. Richey, et al., Effect of left hepatic vein ligation on hepatic circulation, function, and microanatomy in dogs, *Am. J. Vet. Res.* 52 (1991) 774–780.