

Case Report

Coarctation of the Aorta Operated on Adults at the National University Hospital Center Hubert Koutoukou Maga (CNHU-HKM) of Cotonou: About 3 Cases

Abdel Kémal Boribata¹, Murielle Hounkponnou¹, Fifamè Nathalie Adigbonon^{1,*},
Kounapya Désiré Nekoua², Maxwell Nkenhoung¹, Inès Djouking¹,
Théophilia Gracias Mawuton Sahossi¹, Samson Djaouwe Souloukna¹, Codjo Xavier Fadonougbo¹,
François Koukou³, Mathieu Debauchez³, Houétonji Léopold Codjo¹

¹Faculty of Health Science (FSS), University Cardiology Clinic of National University Hospital Center Hubert Koutoukou Maga, Cotonou, Benin

²Faculty of Health Science, Polyvalent University Anesthesia and Resuscitation Clinic of National University Hospital Center Hubert Koutoukou Maga, Cotonou, Benin

³Debmat-Sante, Paris, France

Email address:

nathaliadigbonon@gmail.com (Fifamè Nathalie Adigbonon)

*Corresponding author

To cite this article:

Abdel Kémal Boribata, Murielle Hounkponnou, Fifamè Nathalie Adigbonon, Kounapya Désiré Nekoua, Maxwell Nkenhoung et al. (2023). Coarctation of the Aorta Operated on Adults at the National University Hospital Center Hubert Koutoukou Maga (CNHU-HKM) of Cotonou: About 3 Cases. *International Journal of Cardiovascular and Thoracic Surgery*, 9(6), 77-83. <https://doi.org/10.11648/j.ijcts.20230906.12>

Received: November 9, 2023; **Accepted:** December 6, 2023; **Published:** December 18, 2023

Abstract: *Introduction:* Coarctation of the aorta, a non-cyanogenic congenital heart disease, is a cause of arterial hypertension in young persons, most often managed surgically. We report three cases of coarctation of the aorta in adults operated on at the CNHU-HKM in Cotonou (Benin). *Case presentation:* our three patients were male with a mean age of 23.3 years. Arterial hypertension of the thoracic limbs with hypotension of the pelvic limbs and a decrease in pelvic limb pulses was the clinical presentation observed. All three patients were diagnosed by transthoracic cardiac echocardiography. On thoracic angioscanner, the location was isthmus in all cases. They all underwent surgical resection of the coarctation, with restoration of aortic continuity by interposition of a Dacron prosthetic graft. Post-operative complications included immediate post-operative grade 3 hypertension, one case of chylothorax, one case of pleuropneumopathy and one case of post-operative hemorrhage. At one year, grade 1 hypertension persisted in one patient. *Conclusion:* Coarctation of the aorta can be successfully operated in Benin. Post-operative follow-up must be meticulous, in search of residual hypertension.

Keywords: Coarctation Aorta, Congenital Heart Disease, Hypertension, Adult, Benin

1. Introduction

Coarctation of the aorta is a focal narrowing of the aorta, 95% of which are isthmus, in other words between the origin of the left subclavian artery and the junction between the terminal part of the aortic isthmus and the ductus arteriosus. It represents 5% to 8% of congenital heart defects [1].

Diagnosis can be made at birth by palpation of the femoral

78 Abdel Kémal Boribata *et al.*: Coarctation of the Aorta Operated on Adults at the National University Hospital Center

pulses during the systematic examination of the newborn but can also be made at a later stage in older children or adults [2]. Imaging advances, notably trans-thoracic cardiac ultrasound, CT angiography and MRI, have contributed to the management and follow-up of this pathology and associated lesions [3].

Treatment can be surgical or endovascular. In countries with a low technical platform, radical treatment is often inaccessible. Delays in treatment may be due to a lack of technical resources or financial limitation, as observed in Cameroon by Ndobo-Koe et al [4].

We report three cases of coarctation of the aorta in adults operated on at the CNHU-HKM in Cotonou (Benin).

2. Case Presentation

2.1. Case N°1

Patient X, man aged 28 year old, with arterial hypertension revealed four years ago by intense headaches, was referred to cardiology for resistant hypertension. His treatment consisted of Amlodipine (10mg/day), Perindopril (10mg/day), Nebivolol (5 mg/day) and Hydrochlorothiazide (12.5mg/day). Physical examination revealed asymmetric blood pressure, with hypertension in the thoracic limbs (150/72 mm Hg) and hypotension in the pelvic limbs (83/64 mm Hg), with decreased femoral and pedal pulses. A high perception of the aortic arch pulses at the suprasternal fossa and a suprasternal murmur of intensity 2/6 radiating towards the carotid arteries were also noted. The electrocardiogram (ECG) showed a normal sinus rhythm at 63 bpm and non-specific anteroseptal repolarization abnormalities in the form of asymmetric negative T waves.

The frontal chest X-ray showed a normal cardiothoracic index, a loss of the contour of aortic knob, and rib notching (figure 1).

Transthoracic and transesophageal ultrasonography showed:

- 1) At the cardiac level, an undilated left ventricle with concentric hypertrophy, good segmental kinetics and a 60% systolic ejection fraction on Simpson biplane. There was type 1 L-R bicuspid aortic valve (figure 2) with moderate aortic insufficiency without evidence of stenosis.
- 2) At vascular level, an isthmic coarctation of the aorta (figure 3).

Thoracic Computed tomography (CT) angiography confirmed narrowing of the aortic isthmus with the presence of a marked thoracoabdominal collateral circulation (figure 4). Under general anesthesia with orotracheal intubation, the surgical technic was a left posterolateral thoracotomy through the 4th intercostal space. An aortic coarctation with moderate hypoplasia of the arch was discovered. The coarctation was in the preductal, juxta ductal and post ductal portion of the isthmus (Figure 5 A). The coarctation segment was resected (Figure 5 C), with implantation of an 18 mm-diameter, 5 cm-long dacron prosthetic graft (Figure 5 B).

The postoperative phase was marked by good perception femoral and pedal pulses, and good patency of the prosthesis. At postoperative day 0, a hypertensive crisis was noted, and controlled by injectable Nicardipine followed by antihypertensive triple therapy (AMLODIPINE, PERINDOPRIL AND NEBIVOLOL). However, on the

second postoperative day, he developed a large chylothorax and underwent pleural drainage which produced 1700 cc of triglyceride-rich lactescent fluid at 12 g/l. A low-fat, high-carbohydrate, high-protein diet was instituted, with somatostatin therapy and respiratory physiotherapy. The course of treatment was favorable, with complete regression of the chylothorax after one week.

He also benefited from twelve sessions of adapted cardiac rehabilitation with improved physical performance. He was discharged at 34 postoperative day.

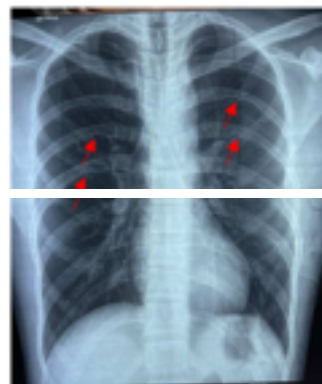


Figure 1. Front thoracic X-ray of CASE N°1 showing rib erosions in the form of an irregular appearance of the inferior cortex of certain ribs: Rib-notching (arrows).

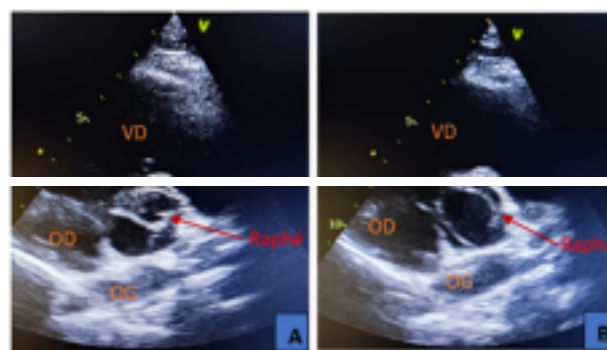


Figure 2. Transthoracic echocardiography image, in short-axis para-sternal incidence, showing type 1 L-R aortic bicuspid aortic valve of case N°1 in closed position (A) and in open position (B).

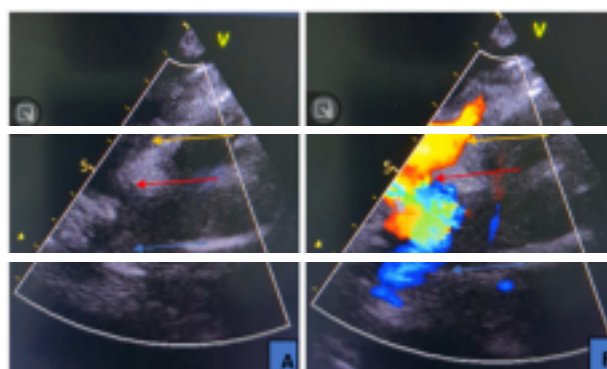


Figure 3. Transthoracic echocardiography image, suprasternal window in two-dimensional mode (A) and with color Doppler (B) showing area of coarctation and flow acceleration (red arrow), left subclavian artery (yellow arrow) and descending aorta (blue arrow) of case N°1.



Figure 4. (A) Thoracic Computed tomography angiography showing isthmic coarctation of the aorta (red arrow). (B) Thoracic Computed tomography (CT) angiography with tridimensional reconstruction showing isthmic coarctation (red arrow), highly developed posterior intercostal collateral arteries (orange arrows) and internal thoracic arteries (green arrows) of case N°1.



Figure 5. (A): intraoperative picture of case N°1 showing the area of coarctation (blue arrow), post-stenotic aortic dilatation (black arrow) and a highly developed intercostal collateral (green arrow). (B) intraoperative picture showing the dacron prosthetic graft (blue arrow) after cure of aortic coarctation. (C) Surgical specimen with opening of the stenosis zone.

At the 1-year follow up visit, he had been off his treatment for one month, blood pressure was normal, and pulses were well and symmetrically perceived. The ECG showed a slow

regular sinus rhythm at 57bpm. Cardiac echocardiography showed good graft patency without complication, and other parameters were unchanged. Ambulatory blood pressure measurement (ABPM) was normal. Nevertheless, he was prescribed a low dose of angiotensin-converting-enzyme inhibitors (ACE inhibitor) for nephroprotection.

2.2. Case N°2

Mr Z, aged 21-year-old had been on antihypertensive monotherapy (Ramipril 10mg/d) for 2 years for hypertension. Clinical examination revealed arterial hypertension of the thoracic limbs (146/72 mm Hg), with a systolic gap of 35mmHg compared to pelvic limbs (pelvic limb BP 111/72 mm Hg); decreased femoral and pedal pulses, upper body arterial hyperpulsatility and a 2/6 systolic murmur at the aortic area.

The electrocardiogram showed normal sinus rhythm at 65 bpm, borderline PR at 200ms, and left ventricular hypertrophy (figure 6).

The frontal chest radiograph was normal.

Transthoracic and transesophageal ultrasonography revealed: 1) At the cardiac level: non-dilated left ventricle with concentric hypertrophy, good segmental kinetics with 60% systolic ejection fraction on Simpson biplane combined with type 0 anteroposterior bicuspid aortic valve, with no leakage or stenosis (figure 7).

2) At vascular level: an initial aortic dilation (aortic sinus at 40mm), suprasternal gradient in the aortic isthmus at 35mmHg (figure 8);

Thoracic CT angiography revealed narrowing of the descending aorta to within 20 mm of the left subclavian followed by moderate dilation of the aorta downstream of the narrowing; collateral circulation involving the costal prevertebral arteries and dorsal soft tissue arteries.



Figure 6. Electrocardiogram of case N°2 set at an amplitude of 5mm/mV showing sinus rhythm with a PR borderline (200ms) and left ventricular hypertrophy. (Peguero Lo Presti Electrocardiographic Index).

80 Abdel Kémal Boribata *et al.*: Coarctation of the Aorta Operated on Adults at the National University Hospital Center Hubert Koutoukou Maga (CNHU-HKM) of Cotonou: About 3 Cases



Figure 7. Transthoracic echocardiography image of case N°2, showing the type 0 anteroposterior bicuspid aortic valve in closed valve position (A) and open valve position (B).



Figure 8. Transthoracic echocardiography image of case N°2, in supra-sternal window, two-dimensional mode (A) showing area of isthmic coarctation (red arrow), flow acceleration on color Doppler (B) and saber blade appearance on continuous Doppler (C).




Figure 9. Intraoperative image of case N°3 showing the area of aortic coarctation stricture pointed by forceps.

Under general anesthesia with orotracheal intubation, the surgical technic was a left posterolateral thoracotomy through the 4th intercostal space. An isthmic coarctation of 2 to 3cm long was discovered, with major development of the intercostals and post stenotic dilatation of the aorta. The coarctation segment is resected in the form of a diaphragm, with a dacron prosthetic graft implantation.

blood transfusion.

Postoperative clinical and paraclinical monitoring showed a good result of the aortic coarctation cure. A hypertensive crisis was noted at postoperative day 0, well controlled by injectable nicardipine followed by dual anti-hypertensive therapy (Ramipril and Amlodipine).

The ECG showed that the rhythm remained sinus.

He underwent twelve sessions of cardiac rehabilitation with improved physical performance and was discharged at 32 postoperative days.

At the 1-year reassessment, the patient had been off treatment for around 10 days. Grade I hypertension

During the acute postoperative phase, he presented a hemothorax resulting to a severe anemia (from 12 to 6g/dl), requiring a return to the operating room for hemostasis and (according to WHO) was noted, with good pulse perception. The ECG was in normal sinus rhythm with a PR limit of 200ms. Echocardiography showed good graft patency with no complications and the other parameters remained unchanged. ABPM showed uncontrolled hypertension requiring therapeutic readjustment.

2.3. Case N°3

Mr Y, aged 21-year-old had been on amlodipine 10mg/d in the last 3 years for treatment of hypertension. The history revealed intermittent chest pain and headache. Physical examination revealed asymmetric blood pressure, with hypertension in the thoracic limbs (148/79 mm Hg), hypotension in the pelvic limbs (89/65 mm Hg) and decreased femoral and pedal pulses. Auscultation revealed a sub clavicular systolic murmur of intensity 3/6.

The electrocardiogram showed a regular sinus rhythm at 68 bpm and negative, asymmetric T waves inferiorly. The frontal chest X-ray was normal.

Transthoracic ultrasound and the transesophageal ultrasound showed:

- 1) Cardiac features: non-dilated left ventricle with concentric left ventricular remodeling, good segmental kinetics with good systolic ejection fraction at 60% on Simpson biplane. There was no aortic valve disease or other cardiac malformation.
- 2) Vascular: isthmic coarctation of the aorta with a sword blade or shark tooth flow pattern.

The thoracic CT angiography revealed a tight constriction of the descending aorta just after the emergence of the left subclavian artery, with post-stenotic dilatation. There was also noted a dilatation of the intercostal arteries with development of a significant thoracic collateral circulation.

Under general anesthesia with orotracheal intubation, the surgical approach was a left posterolateral thoracotomy through the 4th intercostal space. An isthmic aortic coarctation 2-3 cm in length and 2 mm in diameter was discovered, with extensive development of the intercostal and internal thoracic arteries and post-stenotic dilatation of the

aorta. The coarctation segment is resected in the form of a diaphragm (figure 9) with interposition of a dacron prosthetic graft 20 mm in diameter and 5 cm in length.

International Journal of Cardiovascular and Thoracic Surgery 2023; 9(6): 77-83 81

crisis was noted at postoperative day 0, which regressed on injectable Nicardipine followed by triple antihypertensive therapy (AMLODIPINE 10mg/day, RAMIPRIL 10mg/day, BISOPROLOL 5mg/day). On postoperative day 2, he developed left basal pleuropneumonia, successfully treated with double probabilistic antibiotics (ceftriaxone and gentamycin). All 03 blood cultures taken with ceftriaxone were negative.

He was discharged at 34 postoperative days after twelve sessions of cardiac rehabilitation with improved physical performance.

Reassessment at 1 year showed normal blood pressure in all 4 limbs in the absence of antihypertensive treatment for 3 weeks. The ECG was in sinus rhythm with negative, asymmetric T waves in the inferior territory. Echocardiography showed good graft patency with no complications. ABPM showed normal blood pressure. A low dose of Losartan was nevertheless kept for his organs protection.

3. Discussion

Cardiac and vascular surgery is in its beginning in Benin. In this article, we present 03 cases of coarctation of the aorta operated on at the CNHU-HKM in Cotonou. Although the epidemiological and clinical aspects were almost similar, anatomical differences were observed, as were postoperative complications.

Epidemiologically, the mean age of our patients at the time of surgery was 23.3 years, with extremes ranging from 21 to 28 years. In the series by Lakehal R et al, the mean age was 20 years [2]. This result may be explained by late diagnosis. In all patients, the diagnosis was made in adulthood. All were male. This male predominance is found in the literature, with a M/F sex ratio of 2 to 3/1 [5, 6].

Clinically, the circumstances of discovery were hypertension of the thoracic limbs with hypotension of the pelvic limbs and a decrease in the pulses of the pelvic limbs. The aortic stenosis caused by the coarctation creates a pressure gradient that reduces blood pressure distally. This pressure gradient increases collateral circulation to the abdomen and lower limbs, via the intercostal, internal mammary, scapular, and other arteries [7]. This explains the presence of collaterality on CT angiography in all our patients. In case 1, this collateral circulation was evident on the chest X-ray, which showed ribs notching linked to dilatation of the intercostal collateral arteries. These findings had also been made by L. El Oual and Echchikhi Meryem [8, 9].

Hypertension was the main manifestation of coarctation of the aorta in all our patients. Indeed, coarctation of the aorta represents one of the etiologies of secondary hypertension and is found in most adults with coarctation in all series in the literature [5, 10, 11].

Clinical and paraclinical postoperative evaluation showed good results of the aortic coarctation cure; a hypertensive

In one case, the ECG revealed left ventricular hypertrophy. This is an effect of hypertension on the myocardium. It is often found in adults with coarctation of the aorta. Lakehal et al and Bouchart et al found it in 100% and 82% of their patients respectively [2, 5]. This difference may be explained by the small size of our sample.

In terms of imaging, the transthoracic echocardiography is an important test for the hemodynamic assessment of coarctations of the aorta, and for the search for other associated malformations such as bicuspid aortic valve, supra-valvular stenosis, ventricular septal defect, subaortic stenosis, etc. [12]. In our series, the transthoracic echocardiography helped to establish the diagnosis in all 3 cases. Left ventricular function was preserved in all patients, with a mean LVEF of 60%. This result is consistent with those of Majdoub et al [13] in Morocco and Lakehal et al [2] in Algeria, who found a mean LVEF of 65.43% and 64.79% respectively.

Thoracic CT angiography allows precise localization of the coarctation, as well as a good analysis of the collateral circulation and associated vascular anomalies (aneurysms upstream or downstream of the coarctation) [14]. In our series, aortic CT scan was performed in all patients and located the coarctation at the isthmus level. Post-stenotic dilation was noted in two cases.

In 2/3 of our patients, the associated congenital anomaly was bicuspid aortic valve without aortic stenosis. In the literature, the association of bicuspid aortic valve and aortic coarctation is very frequent, as demonstrated by Majdoub and Kristofer, who reported a prevalence of 56% and 48% respectively [13, 15]. It is therefore important to systematically search for bicuspid aortic valve in any patient with a coarctation of the aorta, and vice versa. This aortic valve anomaly may be stenosing or leaky [16]. Moderate aortic insufficiency on bicuspid aortic valve was present in 1 patient. In the study by Majdoub et al [13], 3 out of 7 patients had aortic insufficiency on bicuspid aortic valve. The presence and severity of these associated anomalies must be considered in patient management.

Therapeutically, our 03 patients were treated by a surgical approach consisting of a left posterolateral thoracotomy, the preferred approach for isolated and localized coarctations of the aorta [17]. Surgical treatment remains the gold standard, involving resection of the coarctation with end-to-end suturing of the supra- and substernal stenotic segments (Crafoord procedure) [2, 7, 16]. The technique used to operate on our patient involved resection of the coarctation and restoration of aortic continuity by interposition of a Dacron prosthetic graft. Indeed, in cases of aortic arch mobilization difficulties or native coarctation associated with an ascending aortic aneurysm, the most recommended technique is resection with interposition of a prosthetic graft. In our patients, the difficulty of mobilizing the aortic arch was the obstacle to performing the Crafoord procedure. The same observation was made in the series by Kristofer et al [15], where 93% of patients underwent resection with interposition

of a prosthetic graft due to anatomical constraints.

Early postoperative complications may include infection, hemorrhage, hypertensive crisis, effusion (pleural and pericardial) and paraplegia [2]. In our series, all 03 patients

82 Abdel Kémal Boribata *et al.*: Coarctation of the Aorta Operated on Adults at the National University Hospital Center
Hubert Koutoukou Maga (CNHU-HKM) of Cotonou: About 3 Cases

surge could be explained by dysfunction of the baroreceptors in the carotid sinuses, whose threshold was altered by the coarctation. Its removal leads to sympathetic hyperreactivity and parasympathetic inhibition [19]. Other early complications found in our patients were hemorrhage (01 cases), chylothorax (01 cases) and pulmonary complication (01 cases). We noted no cases of paraplegia. The main risk factor for paraplegia is long aortic clamping time, some authors incriminate the absence of collaterality [20, 21]. A clamping time between 20 and 30 minutes is the limit that should not be exceeded to avoid the occurrence of this serious complication [22]. In our patients, the average clamping time was 53 minutes, with extremes ranging from 44 to 62 minutes, but all our patients had well-developed collaterals, which may explain the absence of paraplegia despite this relatively long aortic clamping time. Long-term evolution may be marked by persistent hypertension, recurrence of aortic coarctation, aortic aneurysm or worsening of associated aortic valve disease. Of our 03 cases, hypertension persisted in only one patient. This result is not consistent with those of Beekman [23] *et al* and Carla *et al* [24], who found persistent hypertension in 47% and 67% of their patients respectively. This persistent hypertension can be explained by the late age of intervention [25]. The ideal age for correction of aortic coarctation is between 6 months and 15 years. Age at surgery was an important predictor of hypertension, and the later the surgery, the greater the risk of hypertension later in life, despite the absence of recurrence of coarctation [26]. The mechanisms of this hypertension are still poorly understood. However, several hypotheses have been put forward, including the persistence of a gradient at the isthmus level, hypoplasia, or a particular gothic-shaped geometry of the aortic arch well visualized on MRI, surgical cure at an older age, an abnormality of the renin-angiotensin-aldosterone system or aortic baroreceptors, or even association with essential hypertension [27-29]. Even after a successful coarctation cure, antihypertensive treatment is often indispensable, with priority given to organ protection effect.

The average duration of hospitalization for our patients was 33 days, with extremes of 32 to 34 days. In the series by Lakehal *et al* [2], the average length of stay was 15 days. This difference can be explained by the level of technical platform and the organization of the health structure in Benin. Indeed, there is not yet follow-up cardiac care and rehabilitation unit. Our patients are therefore kept longer in conventional hospitalization, in the post-operative phase until the end of the cardiovascular rehabilitation sessions.

4. Conclusion

Coarctation of the aorta can occur at any age, from newborns to adults. Hypertension is the most frequent warning sign. Early diagnosis can prevent the risk of

experienced a hypertensive crisis. Our result differs from that of Ledesma M, who found 2 cases of hypertensive out of 56 patients [18]. This difference could be explained by the small number of patients in our study. In fact, this hypertensive

persistent hypertension and associated complications through a variety of surgical techniques. Although cardiovascular surgery in Benin is in its infancy, it has nevertheless employed in the treatment of the 03 cases presented in this article with

satisfactory results. The risk of persistent arterial hypertension and recurrence of coarctation in the chronic postoperative period requires therapeutic education on the importance of long-term continuation of antihypertensive medication and/or organ protection, with regular follow-up of operated patients.

ORCID

Fifamè Nathalie Adigbonon: 0009-0006-0544-8148.

Conflicts of Interest

The authors declare no conflicts of interest.

References

- [1] Gach P, Dabadie A, Sorensen C, Quarello E, Bonello B, Pico H. Imagerie multi-modalités de la coarctation aortique, du fœtus à l'adolescent. *JIDI*. 2016; 97: 215-25.
- [2] Lakehal R, Bendjaballah S, Boukarroucha R, Aimer F, Nazal R, Brahami A *et al*. Chirurgie de la coarctation aortique: à propos de 40 cas. *Batna J Med Sci* 2017; 4 (1): 53-7.
- [3] Warnes CA, Williams RG, Bashore TM, Child JS, Connolly HM, Dearani JA *et al*. ACC/AHA 2008. Guidelines for Adults with CHD. *JACC* 2008; 52 (23).
- [4] Ndofo-Koe V, Mbede M, Nganou-Gnindjio CN, Mfeukeu-Kuate L, Mekone-Nkwele I, Zemsil S *et al*. Coarctation de l'aorte révélée par une hypertension artérielle associée à une insuffisance aortique chez un jeune adulte: à propos d'un cas. *Health Sci Dis*. 2022; 23 (7): 116-9.
- [5] Bouchart F, Dubar A, Tabley A, Litzler PY, Haas-Hubscher C, Redonnet M *et al*. Coarctation of the aorta in adults: surgical results and long-term follow-up. *Ann Thorac Surg*. 2000; 70: 1483-9.
- [6] Albuquerque LC, Goldani MA, Goldani JJ, Araújo RL, Piantá RM, Narvaes LB *et al*. Correção cirúrgica da coarctação da aorta nos primeiros seis meses de vida. *Rev Bras Cir Cardiovasc*. 2002; 17 (2): 29-35.
- [7] Ben el Hosni K, Bouklata S. La coarctation de l'aorte. *Feuill de radiol*. 2011; 51: 280-1.
- [8] El Ouali L, Lahlou I, Laaouze S, Messouak M, Akoudad H. La coarctation de l'aorte chez l'adulte: encore une fois un diagnostic tardif. *JMSM*. 2010; 2: 39-42.
- [9] Echchikhi M, Moatassim BN, Ittimade N. L'exploration de la coarctation de l'aorte chez l'adulte par l'angioscanner: une série de 10 cas. *IJCRT*. 2020; 8: 2901-6.

- [10] Maciej K, Małgorzata I, Zbigniew M, Bany R and Małgorzata U. N. Z. Morphometric evaluation of aortic coarctation and collateral circulation using computed tomography in the adult population. *Acta Radiologica*. 2019; 1–8.
- [11] Rao PS. Coarctation of the aorta. *Curr Cardiol Rep*. 2005; 7: International Journal of Cardiovascular and Thoracic Surgery 2023; 9(6): 77-83 83
- [12] Touma Y, N'Guyen A, N'Guyen N, Assayag P, Kirsch M. Traitement de la coarctation native de l'aorte de l'adulte. *Presse Med*. 2013; 42: 1196-202.
- [13] Majdoub A, Boulmakoul S, Elhafidi A, Moumna A, Messouak M. Résultats chirurgicaux à propos de 07 patients opérés pour coarctation aortique chez l'adulte. *JMSM*. 2020; 22 (4): 13-8.
- [14] Sigal-Cinqualbre A, Lambert V, Ronhean A, Paul JF. Place du scanner multicoupes et de l'IRM dans la stratégie diagnostique des cardiopathies congénitales. *Arch Pédiatr*. 2011; 18 (5): 617-27.
- [15] Charlton-ouw KM, Codreanu ME, Leake SS, Sandhu HK, Calderon D, Azizzadeh A et al. Open repair of adult aortic coarctation mostly by a resection and graft replacement technique. *J Vasc Surg*. 2014; 1-7.
- [16] Vaksmann G, Richard A. Prise en charge de la coarctation de l'aorte chez l'adulte. *Presse Med*. 2011; 40 (7-8): 726-31.
- [17] Roubertie F, Le bret E, Belli E, Roussin R, Ly M, Bensari N et al. Coarctations aortiques et hypoplasie de l'arche. *EMC Tech chir Thoax*. 2010; 1-13.
- [18] Ledesma M, Alva C, Gomez FD, Sanchez-Soberanis A, Diaz y Diaz E, Benitez-Perez C et al. Results of stenting for aortic coarctation. *The Am Cardiol*. 2001; 88: 460-2.
- [19] De Divitiis M, Pilla C, Kattenhorn M, Zadinello M, Donald A, Leeson P et al. Vascular dysfunction after repair of coarctation of the aorta: impact of early surgery. *Circulation*. 2001; 104: 165-70.
- [20] Masson C, Leys D, Meder JF, Dousset V, Pruvo J-P. Ischémie médullaire. *J. Neuroradiol*. 2004; 31: 35-46.
- [21] Cordonnier DLC, Masson C, Pruvo J-P. Infarctus médullaires. *EMC-Neurologie*. 2005; 2: 163-74.
- [22] Vanhulle C, Durand I, Tron P. Paraplegie par ischémie médullaire après cure chirurgicale d'une coarctation de l'aorte. *Arch Pediatr*. 1998; 5: 633-6.
- [23] Ozkokeli M, Gunduz H, Sensoz Y, Ates M, Gunay R, Tayyareci G, et al. Blood pressure changes after aortic coarctation surgery performed in adulthood. *J Card Surg*. 2005; 20: 319-21.
- [24] Canniffe C, Ou P, Walsh K, Bonnet D, Celermajer D. Hypertension after repair of aortic coarctation - A systematic review. *Int J Cardiol*. 2013; 167: 2456-61.
- [25] O'Sullivan J. Late hypertension in patients with repaired aortic coarctation. *Curr Hypertens Rep*. 2014; 16: 421.
- [26] Toro-Salazar OH, Steinberger J, Thomas W. Long-term follow-up of patients after coarctation of the aorta repair. *Am J Cardiol*. 2002; 89: 541-7.
- [27] Christensen NA. Coarctation of the aorta: historical review. *Proc Staff Meet Mayo Clin*. 1948; 23 (15): 322-4.
- [28] Bonnet LM. Sur la lésion dite sténose congénitale de l'aorte dans la région de l'isthme. *Rev Med Paris*. 1903; 23: 108.
- [29] Connolly HM, Huston III J, Brown RD, Warnes CA, Ammash NM, Tajik AJ. Intracranial aneurysms in patients with coarctation of the aorta: a prospective magnetic resonance angiographic study of 100 patients. *Mayo Clin Proc*. 2003; 78: 1491-9.