

Full Length Research Paper

A case of giant ovarian cyst complicated by ascites and pelvic members' vein thrombosis

¹Francis Moïse Dossou, Pierre-Claver Hounkpè², Josiane Angeline Tonato Bagnan³, Roger Sossou⁴, Dansou Gaspard Gbessi⁵, Solange Essola⁵, Justin Dénakpo³, Pascal Sohoun⁵, Kémoko Osséni Bagnan⁵

¹Clinique Universitaire de chirurgie viscérale (CCUV), Centre National Hospitalier Universitaire Hubert K. MAGA (CNHU-HKM), Cotonou, Bénin.

²Service polyvalent d'anesthésie réanimation, CNHU-HKM, Cotonou, Bénin.

³Service de maternité de l'Hôpital de la mère et de l'enfant (HOMEL), Cotonou, Bénin.

⁴Service de radiodiagnostic et d'imagerie médicale de l'HOMEL, Cotonou, Bénin

⁵CCUV, CNHU-HKM, Cotonou, Bénin

Abstract

A 41-years-old patient with a painful abdominal mass moving gradually from 4 months had been received at surgical consultation. Her abdomen was distended by a giant solid mass and by ascites. There was a painful and pitting edema of pelvic members and a bilateral vein thrombosis of pelvic members. A giant serous cystadenoma of the right ovary was discovered at laparotomy. A hysterectomy with bilateral adnexectomy was performed after medical treatment of the thrombosis. The postoperative course was uneventful.

Key-words: Abdominal mass, giant ovarian cyst, venous thrombosis, ascites.

INTRODUCTION

The development of health systems and performance of new technologies have reduced the frequency of giant abdominal tumors by early diagnosis and treatment. However, these tumors have not entirely disappeared since the warning signs are discrete for a long time. In addition, the first complaints, which appear with increasing tumor size, are not specific and may mislead the diagnosis, suggesting ascites (Kaya and Sakarya, 2009). Thus, it increases the risk of complications including thrombotic complications (Timmermans et al., 2009). We report a case of giant ovarian cyst complicated by both ascites and venous thrombosis.

CASE REPORT

A 41-year-old patient, gravidity 8, parity 6, miscarriages

2, had been received in the service for a painful abdominal mass moving gradually from 4 months. She had a known High blood pressure mistreated since 2 years. There was a recent asthenia and weight loss. On examination, there was an impaired general condition, a painful and pitting edema of pelvic members. The abdomen was distended and measured 111cm of perimeter at its largest diameter. The umbilicus was unfolded and there was a collateral circulation (Figure 1). The liver and spleen were not palpated and there was a sloping dullness of the abdomen. Trans-wall puncture brought a sero-hematic liquid. Digital rectal examination was normal. On vaginal examination, the cervix was medial and the lateral cul-de-sac of the vagina was mass less. The rest of the physical examination revealed bilateral pelvic limb pain along the paths of veins.

At sonography and computed tomography (Figure 2), there was a large abdominopelvic fluid mass compressing the surrounding anatomical structures and a medium abundance ascites, but the ovarian origin of the mass couldn't be stated with certainty. Doppler ultrasonography revealed a deep and extent vein

*Corresponding author e-mail : dosfm@yahoo.fr

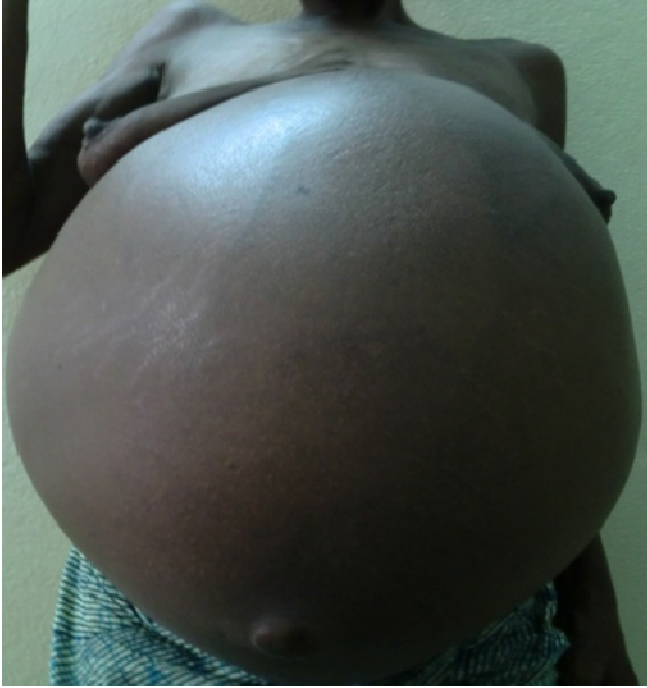

Figure 1: Large abdominal mass with collateral circulation and unfolded umbilicus

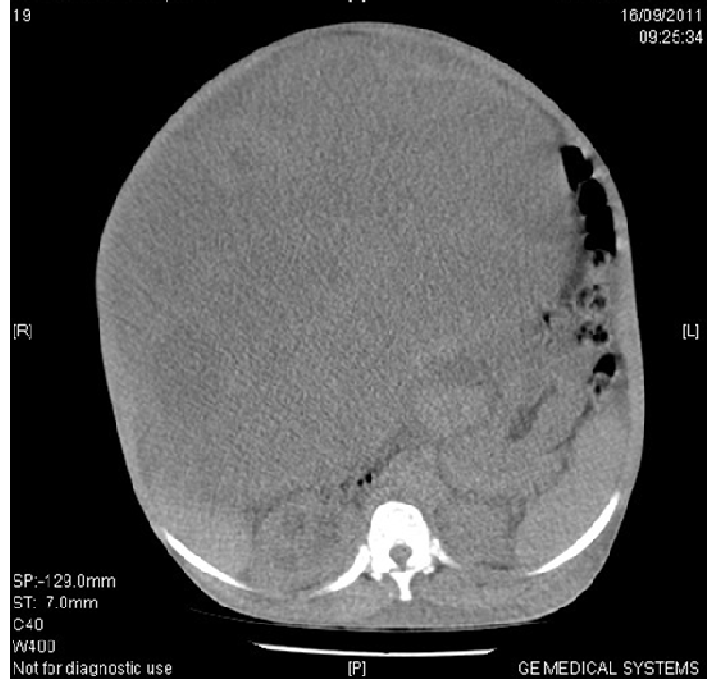

Figure 2: CT Image of the giant ovarian cyst of the right ovary

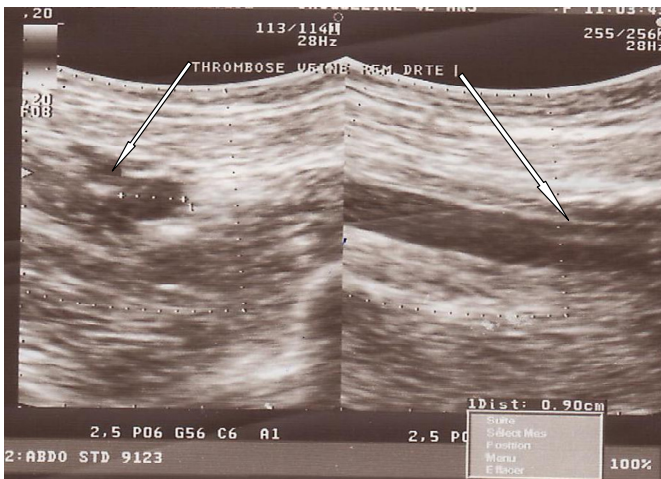


Figure 3: Thrombosis of right femoral vein at Doppler ultrasound (white arrows)

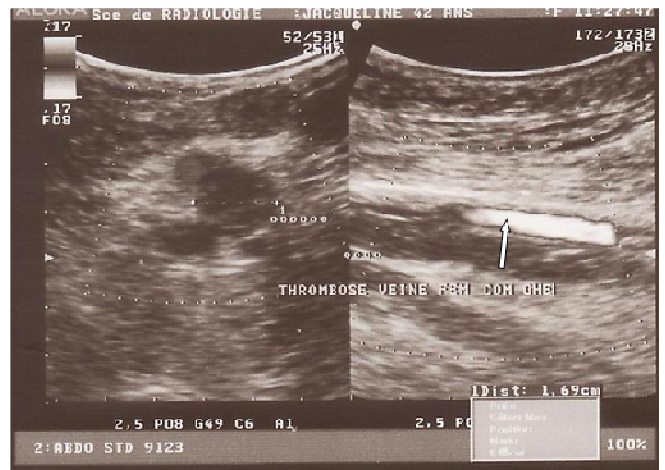


Figure 4: Thrombosis of left femoral vein at Doppler ultrasound (white arrow)

thrombosis of pelvic members (Figure 3 and 4). During two weeks, the patient received anticoagulant therapy based on subcutaneous injections of Enoxaparine (Lovenox™) 12,000 IU per day in 2 doses. After two weeks treatment and clinical amelioration, Acenocoumarol (Sintrom™) was administrated per os 8 mg daily in 2 doses for two other weeks and after that, surgery was performed. There were not repeat Doppler after anti-coagulation. At laparotomy, a large

multi-lobed mass of the right annexes was discovered corresponding to a giant cyst of the right ovary, measuring 44 cm and 36 cm of diameters and weighing 22 kg (Figure 5). Right adnexectomy was performed first, completed by total hysterectomy and left adnexectomy. The other viscera were normal. The postoperative course was uneventful. At pathological examination, it was a benign serous cystadenoma.

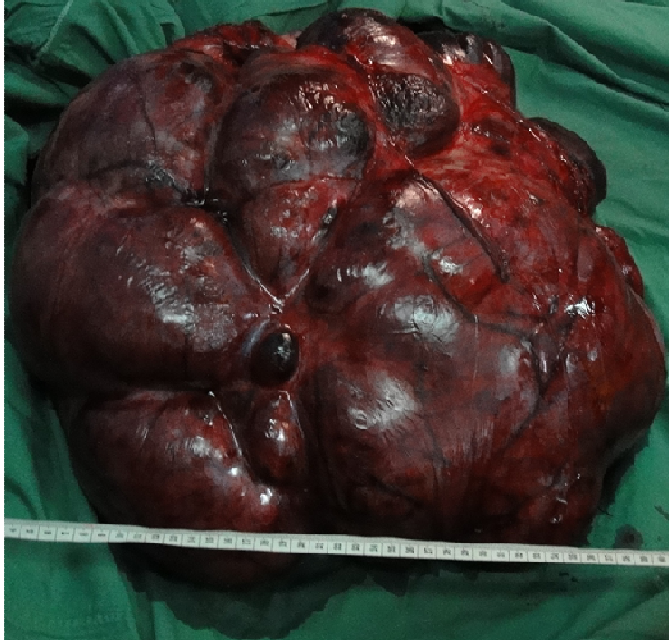

Figure 5: poly-lobed giant ovarian cyst

DISCUSSION

Small ovarian cysts are usually asymptomatic. The first signs appear when the cyst volume increases. Despite persistence of menstruations and because of associated digestive symptoms like nausea and vomiting, the increased volume of the abdomen simulates pregnancy.. At a later stage, the mass can reflect respiratory compression of the diaphragm (Haspels and Zuidema, 1982). Compression of the portal vein induces formation of ascites and collateral paramedian abdominal circulation. The compression of the inferior vena cava induces pelvic limb edema and abdominal collateral circulation and sometimes, it also may be the cause of thrombosis of the aorta (Timmermans et al., 2009). In our observation, it caused a deep and bilateral thrombosis of pelvic members' veins.

Abdominal ultrasound is the main imaging examination in this disease. It confirms the ovarian origin of mass and provides information on cystic nature and its wall structure. However, ultrasound has some limitations when the tumor reaches large. Usually, neither abdominal ultrasound nor CT showed any ovarian abnormality. The final diagnosis of giant ovarian cyst is confirmed after laparotomy and histopathologic examination of the removed specimen (Kaya and Sakarya, 2009). At abdominal ultrasound, differential diagnosis with ascites can be made by not free floating liver and bowel loops and no liquid in paracolic gutters (Mikos et al., 2009). Abdominal CT, ultrasound, and

magnetic resonance imaging are noninvasive studies able to accurately identify cystic structures. Ultrasound appears to yield the most information for the least expense (Kaya and Sakarya, 2009). In the presented case, patient not underwent MR imaging as this examination doesn't exist in our country and the existing CT equipments aren't able to do coronal or sagittal reconstruction.

Treatment of giant cyst of the ovary is a very wide median incision straddles the umbilicus, in order to extract, if possible, the tumor intact to avoid the risk of dissemination in case of carcinoma, but also effusion of fluid in the peritoneal cavity. Some authors advocate laparoscopy (Dolan et al., 2006). In young women wishing to preserve their fertility, conservative treatment is feasible: cystectomy or oophorectomy or adnexectomy, with preservation of the uterus and contra-lateral annex could be realized. In this case, the healthy ovary will be carefully examined to avoid missing a bilateral tumor. Similarly, a sample of peritoneal fluid for cytological analysis is systematic, even if the shape of the tumor is reassuring. In older or postmenopausal patients, a total hysterectomy is preferable, to prevent errors and eventual recurrences. The thrombotic risk of giant ovarian cysts justifies diagnosis of thrombosis by clinical examination and Doppler ultrasound. A perioperative anticoagulant therapy should be performed to prevent complications (Timmermans et al., 2009).

CONCLUSION

The large abdomino-pelvic masses have become curiosities in industrialized countries where the health care system is well developed. Conversely, they are not rare in developing countries. There are no specific characters of the signs of the tumor at this state. The management of the tumor should include correct clinical examination and Doppler ultrasonography to diagnose complications like thrombosis and prevent non favorable issues.

REFERENCES

- Dolan MS, Boulanger SC, Salameh JR (2006). Laparoscopic Management of Giant Ovarian Cyst. *JLS*. 10:254-256.
- Haspels AA, Zuidema PJ (1982). A giant ovarian cyst in a Javanese woman. *BMJ*. 284:1410.
- Kaya M, Sakarya MH (2009). Pseudoascites: Report of three cases. *Turk J Gastroenterol*. 20(3):224-227.
- Mikos T, Tabakoudis GP, Pados G, Eugenidis NP, Assimakopoulos E (2009). Failure of ultrasound to diagnose a giant ovarian cyst: a case report. *Cases Journal*. 2:6909.
- Timmermans J, de Booij M, Strijbos W, Teijink JA (2009). Aortic Thrombosis due to a giant Ovarian Cyst. *EJVES Extra*. 17:33-35.