

P.1.6

Auteurs : Dégboé B, Wanvoegbe A, Gninkoun J, Attinsounon CA, Maffo N, Adégbidi H, Atadokpèdé F, Yèkpè P, Koudoukpo C, Akpadjan F, Agbessi N.

Titre: Acanthosis nigricans during an HAIR-AN syndrome: "the tree that hides the forest".

Référence: Clinical and experimental Dermatology Research Journal, 2017; 8:6. **Facteur d'impact** 2016-2017: **1,65**

URL de l'article/ DOI : 10.4172/2155-9554.1000427

Type de revue : revue indexée dans Worldcat, Genamics, Ulrich's periodicals, Google Scholar, Chemical Abstracts Service (CAS)

ISSN de la revue : 2155-9554

Site web de la revue : <http://clinicalgroup.edmgr.com/>

NLM Catalog

NLM Catalog

journal of clinical and experimental dermatology research

Search

Create alert Advanced

Help



COVID-19 Information



[Public health information \(CDC\)](#) | [Research information \(NIH\)](#) | [SARS-CoV-2 data \(NCBI\)](#) | [Prevention and treatment information \(HHS\)](#) | [Español](#)

Full

Send to

NLM Holdings
in LocatorPlus

Journal of clinical & experimental dermatology research

NLM Title Abbreviation: J Clin Exp Dermatol Res

Title(s): Journal of clinical & experimental dermatology research.

Publication Start Year: 2010

Country of Publication: United States

Publisher: Sunnyvale, CA : OMICS Publishing Group

Language: English

ISSN: 2155-9554 (Electronic)

Electronic Links: Access not provided by NLM

In: PubMed: Selected citations only

Current Indexing Status: Not currently indexed for MEDLINE. Citations are for articles where the manuscript was deposited in PubMed Central (PMC) in compliance with public access policies. For further information, see [Author Manuscripts in PMC](#).

Collection Status: Not in the NLM Collection

NLM ID: 101574132 [Serial]

PubMed Search Builder

Add to search builder

Search PubMed

Search details

```
("periodicals as topic"[MeSH Terms] OR ("periodicals"[All Fields] AND "topic"[All Fields]) OR "periodicals as topic"[All Fields] OR "journal"
```

Search

See more...

Recent Activity

Turn Off Clear

journal of clinical and experimental dermatology research (1) NLM Catalog

Les nouvelles dermatologiques (1)



ISSN: 2155-9554

Journal of Clinical & Experimental Dermatology Research

search

Case Report ▶ J Clin Exp Dermatol Res 2017, Vol 8(6): 427 DOI: 10.4172/2155-9554.1000427

Acanthosis Nigricans during an HAIR-AN syndrome: "The Tree That Hides the Forest"

Dégboé B^{1*}, Wanvoegbe A², Gninkoun J², Attinsounon CA³, Maffo N¹, Adégbidi H¹, Atadokpèdé F¹, Yèkpè P⁴, Koudoukpo C⁵, Akpadjan F¹ and Agbessi N⁵

¹Department of Dermatology Venerology, Faculty of Health Sciences, [University of Abomey-Calavi](#), Benin

²Department of Internal Medicine and Endocrinology, Faculty of Health Sciences, [University of Abomey-Calavi](#), Benin

³Teaching and Research Unit of Infectious and Tropical Diseases, Faculty of Medicine, [University of Parakou](#), Benin

⁴Department of Radiology, Faculty of Health Sciences, [University of Abomey-Calavi](#), Benin

⁵Department of Dermatology Venerology, Faculty of Medicine, [University of Parakou](#), Benin

* **Corresponding Author:** Dégboé B, Department of Dermatology Venerology, Faculty of Health Sciences, [University of Abomey-Calavi](#), Benin, Tel: +22996960005, +22995497341, Email: kebdegboe@yahoo.fr

Acanthosis Nigricans during an HAIR-AN syndrome: "The Tree That Hides the Forest"

Dégboé B^{1*}, Wanvoegbe A², Gninkoun J², Attinsounon CA³, Maffo N¹, Adégbidi H¹, Atadokpèdé F¹, Yèkpè P⁴, Koudoukpo C⁵, Akpadjan F¹ and Agbessi N⁵

¹Department of Dermatology-Venerology, Faculty of Health Sciences, University of Abomey-Calavi, Benin

²Department of Internal Medicine and Endocrinology, Faculty of Health Sciences, University of Abomey-Calavi, Benin

³Teaching and Research Unit of Infectious and Tropical Diseases, Faculty of Medicine, University of Parakou, Benin

⁴Department of Radiology, Faculty of Health Sciences, University of Abomey-Calavi, Benin

⁵Department of Dermatology-Venerology, Faculty of Medicine, University of Parakou, Benin

*Corresponding author: Dégboé B, Department of Dermatology-Venerology, Faculty of Health Sciences, University of Abomey-Calavi, Benin, Tel: +22996960005, +22995497341; E-mail: kebdegboe@yahoo.fr

Received date: September 20, 2017; Accepted date: October 16, 2017; Published date: October 20, 2017

Copyright: ©2017 Dégboé B, et al. This is an open-access article distributed under the terms of the Creative Commons Attribution License, which permits unrestricted use, distribution, and reproduction in any medium, provided the original author and source are credited.

Abstract

Introduction: Acanthosis nigricans is broadly classified into malignant and benign forms. Recent attention has been directed toward its benign endocrine associations. Acanthosis nigricans is a significant marker for insulin resistance.

Observation: A 20-years-old girl has consulted for macular, hyperpigmented, papillomatous lesions which were on the neck with overflows on the mandibular areas and the ears, in the vertebral groove, the armpits, and the umbilicus. These lesions were associated with a clinical syndrome of hyperandrogenism. The blood sample showed hyperglycemia at 1.3 g/dl, hyperprogesteronemia at 0.63 ng/mL, hypertestosteronemia at 0.87 ng/mL and hypercholesterolemia at 2.63 g/L. Ultrasound of the uterus showed polycystic ovaries. The diagnosis of HAIR-AN syndrome was concluded and the patient was treated.

Conclusion: HAIR-AN syndrome is a rare condition which is characterized by an unusual multisystem disorder in women.

Keywords: Acanthosis nigricans; Hyperandrogenism; HAIR-AN; Insulinin resistance

Introduction

Acanthosis nigricans (AN) is characterized by warty papillomatous lesions of brownish color and velvety appearance predominating in folds. It may be indicative of either a paraneoplastic syndrome or an insulin resistance. In the latter case we will conclude that it is a benign AN [1-4]. The benign AN is an important indicator of hyperinsulinemia due to insulin resistance. It may be associated with genetic syndromes or developed after taking certain drugs or on obesity grounds [1,2,4-6]. We report a case of benign AN that reveals a genetic insulin resistance syndrome.

Case:

A 20-years-old girl with a history of spaniomenorrhœa and menorrhagia was consulted for black spots with a granite surface that have been expanding since the age of 10 and are mistaken for a side phenomenon of lack of hygiene. There were macular, hyperpigmented, papillomatous surfaces and placards, poorly defined. These lesions were on the neck (Figure 1) with overflows on the mandibular areas and the ears, in the vertebral groove, the armpits (Figure 2), and the umbilicus.



Figure 1: Warty papillomatous lesions of brownish color and velvety appearance on the neck in a young woman with HAIR-AN syndrome.

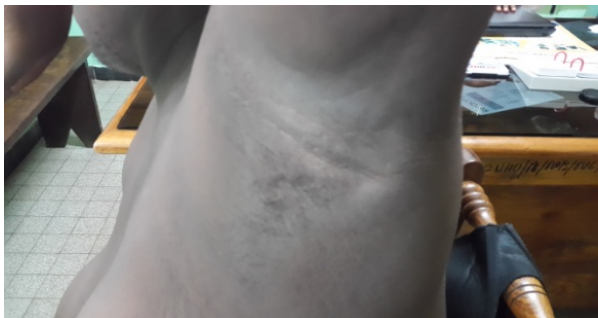

Figure 2: Warty papillomatous lesions of brownish color and velvety appearance in the armpit in a young woman with HAIR-AN syndrome.

The mucous membranes were unaffected. The other aspects of the checkup revealed a clinical syndrome of hyperandrogenism that included hirsutism, retentional acne and android obesity with a body mass index of 32.8 kg/m². Hirsutism was defined by increased hairiness of the chin (Figure 3) and limbs, losangic pilosity of the abdomen. The blood sample showed hyperglycemia at 1.3 g/dL (normal value: 0.72-1.18 g/dL), hyperprogesteronemia at 0.63 ng/mL (normal value: 0.25-0.54 ng/mL), hypertestosteronemia at 0.87 ng/mL (normal value: 0.2-0.5 ng/mL) and hypercholesterolemia at 2.63 g/L (normal value: 1.25-2.25 g/L) while Follicle Stimulating Hormone (FSH), Luteinizing Hormone (LH), prolactin and 17-hydroxyprogesterone were normal. Normal cortisoluria and blood ionogram made it possible to reject Cushing's syndrome. In the presence of hormonal disturbances, ultrasound of the uterus was requested and showed polycystic ovaries. The diagnosis of HAIR-AN syndrome was concluded. The patient was treated with tretinoin 0.05. After advice from the endocrinologist, she was received metformin (1000 mg/day) associated with dietary solutions. The electrocardiogram was normal. Psychological follow-up was requested.

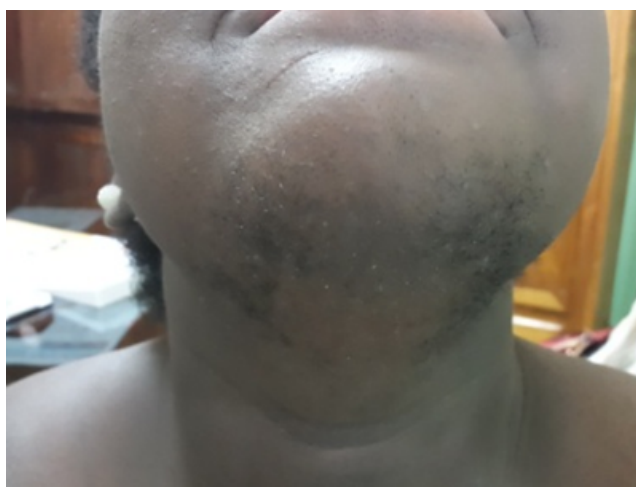

Figure 3: Increased hairiness of the chin definite hisurtism in a young woman with HAIR-AN syndrome.

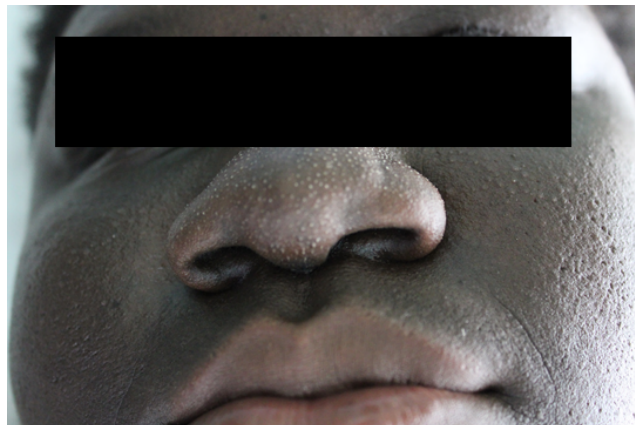


Figure 4: Retentional acne on the face in a young woman with HAIR-AN syndrome.

Discussion

Kahn et al. described genetic insulin resistance syndromes of type A and B. Type A, referred to with the acronym HAIR-AN syndrome, associates hyperandrogenism (HA), insulin resistance (IR) and acanthosis nigricans (AN). Type B IR is caused by circulating antibodies directed against the insulin receptor and is often associated with other autoimmune diseases [1,2,5,7].

HAIR-AN syndrome is observed with 1% to 5% of young women with hyperandrogenism, particularly with young black African women. Our patient is a young black woman as described. Its prevalence may be underestimated because of its often insidious manifestations. It is a rare condition which is characterized by an unusual multisystem disorder in women with many cases remaining undiagnosed [1,5,7-11].

Insulin resistance is due to the mutations in the insulin receptors encoding gene that induce the synthesis of a truncated messenger ribonucleic acid (mRNA). The excess circulating insulin would stimulate insulin growth factor receptors (IGFR) located on keratinocytes and melanocytes of the epidermis, thus causing AN. Circulating insulin can also stimulate the stromal cells and the ovary granulosa and lead to the excess production of androgens responsible for the manifestations of hyperandrogenism. Hyperinsulinemia and associated hyperandrogenism will cause other metabolic, gynecological and psychiatric comorbidities. [1,2,4,5,9,10].

Its diagnosis is based on clinical and paraclinical explorations. In addition to the acanthosis nigricans, the clinical examination reveals the signs of virilization, namely the hisurtism, an android obesity, a hypertrophy of the clitoris, a muscular hypertrophy, an increased libido. Apart from virilization, other signs of hyperandrogenism include menstrual disorders such as amenorrhea, hypofertility or sterility, retentional acne, and androgenetic alopecia. If the patient has polycystic ovaries together with signs of hyperandrogenism, the syndrome of polycystic ovary is concluded [3,5,7,10,12].

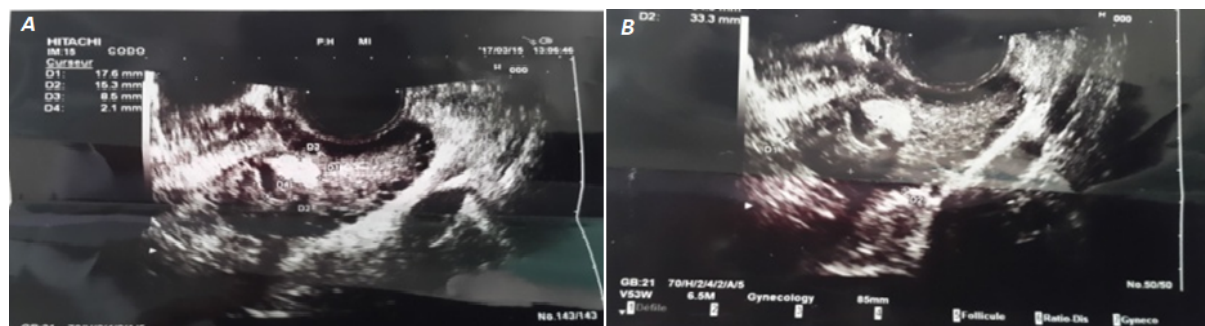


Figure 5: Polycystic ovaries revealed by ultrasound of the uterus in a young woman with HAIR-AN syndrome in both ovaries A: Left, B: Right ovaries respectively.

Patients with HAIR-AN syndrome usually have a high serum level of testosterone, A normal urine level of 17-ketosteroids, 17-hydroxyprogesterone, dihydroepiandrosterone (DHEA) and normal serum level of basal gonadotrophins (LH, FSH). Normal blood ionogram and cortisoluria make it possible to reject Cushing's syndrome [2,5,7,10,12].

The assessment of comorbidities induced by the association of hyperinsulinemia and hyperandrogenism includes lipidogram and cardiovascular examination in search of atherosclerotic risk factors [1,3,6-8]. In some cases, there may be psychiatric disorders of organic origin. The aesthetic damage caused by skin lesions, combined with functional damage from systemic hurts, often leads to real psychological disturbances [10,13,14].

There is currently no therapeutic consensus. It is conclusive to apply diet and physical activities to reduce overweight. The specific therapeutic options for reducing hyperinsulinemia include the analog octreotide of the somatostatin synthesis, metformin, a biguanide compound used in type 2 diabetes, and thiazolidinediones. Oestrogenic contraceptives, spironolactone, flunamide, androcur and α -reductase inhibitors reduce certain manifestations of hyperandrogenism. Tretinoin, local application of vitamin D3 derivatives, oral isothretinoids or the long-pulsed Alexandrite laser are some means used to reduce acanthosis nigricans [1-3,9]. Our patient was treated with tretinoin 0.05, metformin (1000 mg/day) associated with dietary counseling.

Conclusion

Our observation confirms the importance of internal diseases cutaneous signs. Acanthosis nigricans is an early and frequent indicator of genetic insulin resistance syndromes. Beyond the aesthetic concerns that often motivate consultation in the HAIR-AN syndrome, there is a real issue of metabolic, cardiovascular, cerebral, gynecological and psychiatric comorbidities. The therapeutic challenge remains that of insulin resistance.

References

1. De Schepper S, Naeyaert JM (2006) Acanthosis nigricans. In *Encyclopédie medico-chirurgicale*, Elsevier SAS Edition: 98-670.
2. Hermanns-Lê, Scheen A, Piérard GE (2004) Acanthosis Nigricans Associated with Insulin Resistance. *Am J Clin Dermatol* 5: 199-202.
3. Rager KM, Omar HA (2006) Androgen Excess Disorders in Women: The Severe Insulin-Resistant Hyperandrogenic Syndrome, HAIR-AN. *Sci World J* 24: 116-123.
4. Napolitano M, Megna M, Monfrecola G (2015) Insulin Resistance and Skin Diseases. *Sci World J* 1-11.
5. Esperanza LE, Fenske NA (1996) Hyperandrogenism, insulin resistance and acanthosis nigricans (HAIR-AN) syndrome: spontaneous remission in 15-years-old girl. *J Am Acad Dermatol* 34: 892-897.
6. Schilling WKH, Crook MA (2014) Cutaneous stigmata associated with insulin resistance and increased cardiovascular risk. *Int J Dermatol* 53: 1062-1069.
7. Elmer KB, George RM (2001) HAIR-AN Syndrome: A Multisystem Challenge. *Am Fam Physician* 63: 2385-2390.
8. Manco M, Castagneto M, Nanni G, Guidone C, Tondolo V et al. (2005) Biliopancreatic Diversion as a Novel Approach to the HAIR-AN Syndrome. *Obes Surg* 15: 286-289.
9. Dédjan AH, Chadli A, El Aziz S, Farouqi A (2015) Hyperandrogenism-Insulin Resistance-Acanthosis Nigricans Syndrome. *Case Rep Endocrinol* 1-4.
10. Omar H A, Logsdon S, Richards J (2004) Clinical Profiles, Occurrence, and Management of Adolescent Patients with HAIR-AN Syndrome. *Sci World J* 4: 507-511.
11. Pfeifer SLE, Wilson RM, Gawkrödger DJ (1999) Clearance of acanthosis nigricans associated with the HAIR-AN syndrome after partial pancreatectomy: an 11-year follow-up. *Postgrad Med J* 75: 421-422.
12. Barbieri RL, Smith S, Ryan KJ (1988) The role of hyperinsulinemia in the pathogenesis of ovarian hyperandrogenism. *Fertil Steril* 50: 197-212.
13. Morales-Rosello José (1995) HAIR-AN syndrome and mental disorders. *J Neuropsychiatry Clin neurosci* 7: 538.
14. Levin TR, Tharell TR, Stoudemire A (1992) Organic mood disorder associated with the HAIR-AN syndrome. *J Neuropsychiatry Clin neurosci* 4: 51-54.