

## Effect of Corticosteroid Injection among West African People Suffered from Levator Scapulae Syndrome

Zomalheto Z<sup>1\*</sup>, Adjadohoun S<sup>2</sup>, Dossou-yovo H<sup>1</sup> and Gounongbe M<sup>1</sup>

<sup>1</sup>Rheumatology Department of National Hospital, University Hubert Koutoukou Maga of Cotonou, Benin

<sup>2</sup>Radiology Department of National Hospital, University Hubert Koutoukou Maga of Cotonou, Benin

\*Corresponding author: Zomalheto Zavier, Rheumatology Department of National Hospital, University Hubert Koutoukou Maga of Cotonou, Benin, Tel: 00229 95 01 77 79; E-mail: zozaher@yahoo.fr

Received date: September 19, 2017; Accepted date: September 27, 2017; Published date: October 10, 2017

Copyright: ©2017 Zomalheto Z. This is an open-access article distributed under the terms of the Creative Commons Attribution License, which permits unrestricted use, distribution, and reproduction in any medium, provided the original author and source are credited.

### Abstract

**Aim:** To evaluate the effect of corticosteroid injection in patients with levator scapulae syndrome in the National Hospital University Hubert Koutoukou, Maga of Cotonou (Benin).

**Methods:** A prospective case-control study was conducted from October 2016 to June 2017. The selected patients suffered from levator scapulae syndrome received three corticosteroid injection at one week interval compared to a control-group with the same disease treated with medical drugs and anesthetic injection. Demographic data, clinical parameters and outcomes during six months were collected. The primary endpoint was the reduction of visual analog score (VAS). Quality of life was assessed using the Short Form-36 Health Survey (SF-36).

**Results:** Twenty-three (23) patients received corticosteroid injection against twenty-one (21) in the control group. The mean age was  $37.43 \pm 12.02$  (24-59) years and  $36.01 \pm 11.8$  and the sex ratio was 1.55 (14/9) and 1.3 (12/9), respectively in the "injection group" and "control group." All patients had a VAS  $\geq 6$ . At one, three and six months, 21 (94.3%), 19 (82.6) and 16 (69.5) patients had, respectively more than 75% pain reduction in the injection group against 6 (26.1%), 3 (14.2) and 2 (8.7) patients in the control group ( $p=0.035$ ,  $0.011$  and  $0.013$  respectively). After 6 months, physical and mental composite scores of SF-36 in the injection group were significantly higher than those of the control group ( $p=0.001$ ).

**Conclusion:** The injection of corticosteroid is an effective therapeutic in the treatment of the levator scapulae syndrome. It should be performed with another study and may be repeated after six months in patients.

**Keywords:** Levator scapulae syndrome; Corticosteroid injection; Benin

### Introduction

The levator scapulae muscle is located at the side and back of the neck. It is one component of the muscular system of the shoulder. Its primary function is to lift the scapula, which is the triangle-shaped bone located at the back of the shoulder that connects the upper arm bone with the clavicle. The levator scapula originates from the posterior tubercle of the transverse process of cervical vertebrae one to four. The muscle is inserted into medial border of the scapula extending from superior angle to junction of spine and medial border of scapula [1]. When the spine is fixed, levator scapulae elevates the scapula and rotates its inferior angle medially it often works in combination with other muscles like the rhomboids and pectorals minor to rotate down [2]. The levator scapulae are supplied by two or three branches of the fourth and fifth cervical nerves, and frequently by a branch from the dorsal scapula [3]. It may be the site of chronic pain; very painful myofascial syndrome often misunderstood by practitioners. This myofascial pain syndrome occurs in 30% of patients in pain clinics and reduces quality of life and sometimes causes psychological problems such as anxiety or depression [4,5]. Levator scapulae syndrome is one of the most frequently affected muscles.

Pains are often atypical and can have several revealing modes. It may involve back pain, neck pain or shoulder pain. These pains sometimes radiate in the lower dorsal regions or in a thoracic limb causing the patients to wander to the cardiologists. This syndrome is often unresponsive to pharmacological or non-pharmacological treatments. Many treatments have been used for this syndrome especially stretching exercises, trigger point injection, acupuncture, and intramuscular electric stimulation [6]. However, the clinical effects of these treatments, such as the degree of pain relief, duration of pain relief, and quality of life, were not clearly demonstrated. In addition, in our clinical practice, the effect of the corticosteroid injection was not studied among the patients. In the current study, we evaluated the effect of corticosteroid injection in levator scapulae syndrome by comparing to simple medical treatment.

### Materials and Methods

This study was a prospective, randomized, case-control trial. Patients were recruited from the rheumatology department of National hospital University hubert Koutoukou Maga of Cotonou from October 2016 to July 2017. Forty-four patients (26 men, 18 women; mean age  $36.72 \pm 11.91$  (24-59) years) were recruited according to the following inclusion criteria:

1. Having consulted in the Rheumatology Hospital Unit during the study period.
2. Have suffered from myofascial pain (high back pain or neck pain or shoulder pain with or without radiculagia on the thoracic limb) related to levator scapulae syndrome. This syndrome is retained on the basis of pain in the before mentioned seats that is not confined to 1 dermatome or myotome during physical examination (patient in sitting position, the practitioner backwards causes a forced latero-reflexion of the head with one hand and performs deep palpation along the path of the muscle with the other hand) [7], and the presence of taut bands in the levator scapulae muscle with 1 or more identifiable trigger points along the muscle (cervical or scapulae insertion).
3. Symptoms persisted for at least 3 months.
4. Normal results on the neurological examination, included deep tendon reflexes, manual muscle testing, and sensory exam.
5. Have had the appointments of follow-up visit for 6 months.
6. Have consented for the study.

The exclusion criteria were as follows:

1. The presence of other diagnoses such as herniated cervical disc, cervical spinal stenosis, or nerve entrapment syndromes, other rheumatic disease which can cause myofascial pain.
2. Pregnancy.
3. The presence of coagulopathy, or the use of anticoagulants.
4. Informed consent was obtained from all participants. This study was approved by the Ethical committee of the National hospital University.

Based on Won-Sik Bae study [8], we needed to recruit 18 subjects.

Forty-four patients with levator scapula syndrome were randomly assigned to 2 groups according to the criteria. The first group called "injection group" received medical treatment in the form of analgesics and anti-inflammatory drugs associated with three corticosteroid injection (betamethasone) at one week interval. The "control-group" received medical treatment and anesthetic injection. The analgesics used included tramadol or acetaminophen only or combined with codeine and the anti-inflammatory drugs used were diclofenac, ketoprofen or piroxicam. 1 ml corresponding to 7 mg dose of betamethasone was administered. Injections were performed in sitting position by three experienced Rheumatologists specialized in interventional Rheumatology. For the injection, we used a procedure described by Domingo et al. [7], the trigger point was established using physical signs (forced latero-flexion of the head with one hand and performed deep palpation along the path of the muscle with the other hand). Then, the skin over the tender area was marked. The skin was sterilized using iodised alcohol. After all the preparation steps above, a 22-gauge 10 cm cannula with a 10 mm active tip was inserted into the trigger point of the levator scapulae muscle (loco dolenti injection). Before starting the injection, 5 mL of 2% lidocaine was infused through the cannula. After 1 ml of betamethasone been injected through the cannula. This injection was performed three times at one week interval.

In the control group, all the preparation steps were the same as the injection group but we used only anesthetic (we injected 5 mL of 2% lidocaine three times at one week interval). These procedures were performed for each patient by the same physician who has 10 years of training and experience. The physician who performed the procedures was not involved in measuring outcomes. Analgesic treatment was

maintained throughout the study period while the anti-inflammatory drugs were stopped after two weeks of continuous intake. We did not notify any complications after the procedure.

Data collection was initially done using a survey form which were identified the general characteristics (age, sexes), visual analog scale (VAS), the physical component score (PCS) and mental component score (MCS) of Short Form 36 Health Survey (SF-36), which is a well-known generic measure of health-related quality of life for the two groups. The VAS for pain and SF-36 of patients were recorded in three follow-up visits at one, three and six months.

The primary endpoint was the reduction of visual analogue score (DVAS). The severity of pain was recorded on a 100 mm. VAS where 0 means no pain and 100 represents the most severe pain. The outcome was considered satisfactory when the reduction of VAS (DVAS)>75% and poor when DVAS<25%. The secondary outcome measurement was performed using the PCS and MCS of SF-36 evaluated at six months after the treatment. The patients provided informed consents and ethical approval was obtained by the National Hospital University committee.

Statistical analysis: Data were analysed using epidata and SPSS 18.0 software. Chi-square test was used to compare the differences between both groups. Statistical significance was set at  $p < 0.05$ . The data were expressed as frequency, range mean  $\pm$  standard deviation (S.D), odds ratio and 95% confidence interval (CI).

## Results

### Demographic characteristics

There were 44 patients from 7 countries in West Africa (29 from Benin, 5 from Togo, 4 from Nigeria, 2 from Burkina Faso, 1 from Nigeria, 1 from Mali, 2 from Senegal). There were 23 subjects in the test group and 21 in the control group. The mean ages of the test and control groups were  $37.43 \pm 12.02$  and  $36.01 \pm 11.8$  years, respectively. The sex ratio was 1.55 (14 men and 9 female) and 1.3 (12 men and 9 female), respectively in the "injection group" and "control group." All patients had a VAS  $\geq 6$ . The average PCS and MCS of these groups were  $38.5 \pm 4.4$  and  $39.8 \pm 9.3$  for the test group and  $38.2 \pm 6.2$  and  $40.1 \pm 12.3$  for the control group. The general characteristics of the study subjects are shown in Table 1.

Characteristics	Injection group	Control group	P
Number	23	21	
Mean age (years)	$30.78 \pm 8.79$ (17-51)	$30.57 \pm 9.6$ (17-52)	0.721
Sex ratio (male/female)	1.55	1.3	0.824
Mean VAS (mm)	$75.60 \pm 11.18$ (60-100)	$74.14 \pm 9.43$ (61-95)	0.45
SF-36			
PCS	$38.13 \pm 4.96$ (31-48)	$37.04 \pm 4.68$ (30-47)	0.824
MCS	$36.78 \pm 3.83$ (30-45)	$36.52 \pm 4.40$ (29-44)	0.9

**Table 1:** Characteristics of the two groups.

### Outcomes of VAS among the two groups

After one, three and six months there was a statistically significant difference in the reduction of VAS between the 2 groups ( $p < 0.000$ ) (Figure 1).

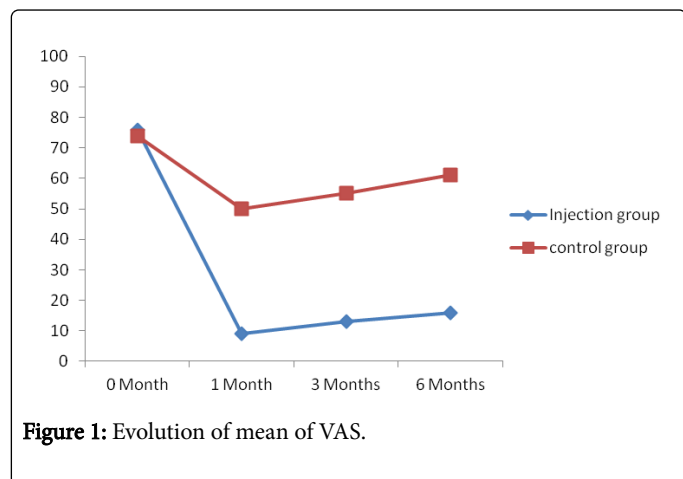


Figure 1: Evolution of mean of VAS.

At one, three and six months, 21 (94.3%), 19 (82.6) and 16 (69.5) patients had, respectively more than 75% pain reduction against 6 (26.1%), 3 (14.2) and 2 (8.7) patients in the control group ( $p < 0.0001$ ,  $p < 0.001$  and  $p < 0.0001$  respectively) (Table 2).

	Injection group N (%)	Control group N (%)	$\chi^2$ P
1 Month			
DVAS > 75%	21 (94.3)	6 (26.1)	18.221
DVAS < 25%	2 (5.7)	15 (73.9)	<0.001
3 months			
DVAS > 75%	19 (82.6)	3 (14.2)	20.496
DVAS < 25%	4 (17.4)	18 (85.8)	<0.0001
6 months			
DVAS > 75%	16 (69.5)	2 (8.7)	16.371
DVAS < 25%	7 (30.5)	19 (91.3)	<0.001

Table 2: Outcomes of the pain of the patients in two groups.

### Evolution of SF-36 score

After one, three and six months, physical and mental component scores of SF-36 in the injection group were significantly higher than those of the control group ( $p = 0.033$ ,  $0.039$ ,  $0.048$  respectively for PCS and  $0.035$ ,  $0.029$ ,  $0.05$  respectively for MCS) (Figures 2 and 3).

### Change in pharmacologic drugs consumption

The number of patients who did not take any medication after six months was significantly higher in the injection group in contrast to the control group (19 patients versus 5 and  $p = 0.033$ ).

### Discussion

Levator scapulae syndrome is one of the most frequently affected muscles. It is characterized by a motor abnormality (a taut or hard band within the muscle) and by sensory abnormalities (tenderness and referred pain). It is classified as a musculoskeletal pain syndrome that can be acute or chronic, regional or generalized. It can be a primary disorder causing local or regional pain syndromes, or a secondary disorder that occurs as a consequence of some other condition. Pains are often atypical and can have several revealing modes [8,9]. The hospital frequency of this pathology and the young age of the patients observed in our study attest to the cosmopolitan character of this syndrome in young adults. The prevalence of this syndrome in the population is variable with rates above 80% among neck pain [9].

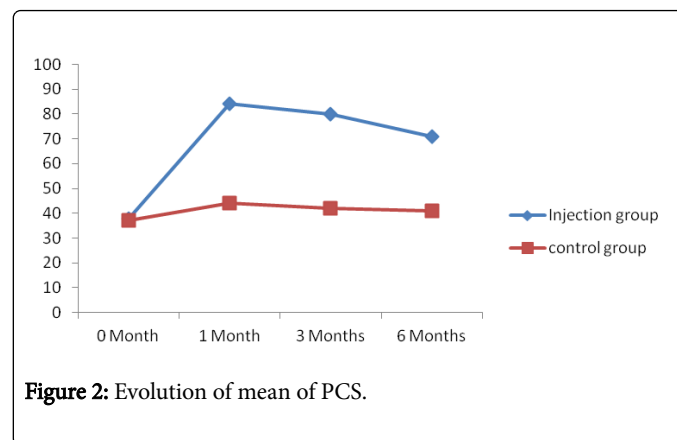


Figure 2: Evolution of mean of PCS.

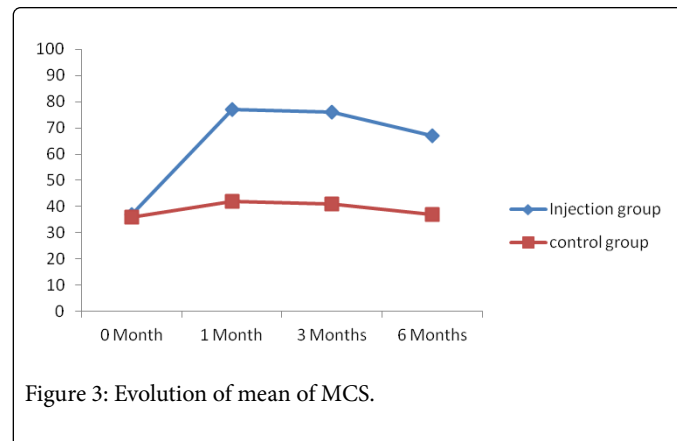


Figure 3: Evolution of mean of MCS.

Most free nerve endings of muscles are known to be nociceptive, which are connected to the central nervous system by thin myelinated (A-delta) and unmyelinated (C) afferent fibers. The nociceptive free nerve endings and the afferent nerve fibers predominantly contain, prostaglandin and others substances, which play important roles in the development of pain. The free nerve endings containing these substances are abundantly located around muscle fascia [5]. The occurrence of levator scapulae syndrome is attributed to the excitement of the free nerve endings inside the muscle fascia. Recently, studies have reported that interfascial block, relieved myofascial pain by reducing the excitability of these nerve endings [10-12].

In our study, we evaluated the clinical effect of corticosteroid injection in patients with levator scapulae syndrome compared to lidocaine injection. Indeed, the main mechanism of action of corticosteroids is to block the local inflammation triggered by

neurotransmitters including prostaglandin. Our results showed that the severity of pain, which was measured using the VAS, was significantly reduced after corticosteroid injection. At 6 months, the degrees of pain reduction were lower in the different groups but remain effective in the injection group.

In addition, although SF-36 PCS and MCS at one, three and six months post-treatment were increased in both groups, the patients in the injection group showed higher scores compared to the control group. Higher SF-36 PCS and MCS are indicative of higher physical and mental quality of life, respectively. Therefore, our results indicate that corticosteroid injection can provide better physical and mental quality of life in patients with levator scapulae syndrome.

Work on levator scapulae syndrome is rare and the short- and long-term effect of corticosteroid injection has not been explored [13]. To the best of our knowledge, this study is the first clinical investigation to examine the immediate and long term effects of corticosteroid injection in the levator scapulae syndrome by evaluating pain reduction and PCS and MCS among the patients after treatment. However, several other therapeutic means such as neurological blocks, acupuncture myofascial syndromes were evaluated with demonstrated short-term efficacy. Our results were correlated with those of Abbaszadeh-Amirdehi M and Ustun N, who showed that intra-operative pain control with dry needling significantly reduced pain and fatigue and improve the quality of life of patients.

## Conclusion

The results of this study showed that corticosteroid injection in the levator scapulae syndrome appears to reduce pain and improve the MCS and PCS scores. Others studies more than 6 months duration are recommended to assess the additional effect of the injection.

## References

1. Brand RA (2008) Origin and Comparative Anatomy of the Pectoral Limb. *Clin Orthop Relat Res* 466: 531-542.
2. Platzer W (2004) *Color Atlas of Human Anatomy: Locomotor System* (5th edn), Thieme.
3. Rockwood C, Matsen F, Wirth M, Lippitt S (2009) *The shoulder* (5th edn), Elsevier.
4. Skootsky SA, Jaeger B, Oye R (1989) Prevalence of myofascial pain in general internal medicine practice. *West J Med* 151: 157-160.
5. Cerezo-Téllez E, Torres-Lacomba M, Mayoral-Del MO, Sánchez-Sánchez B, Dommerholt J, et al. (2016) Prevalence of Myofascial Pain Syndrome in Chronic Non-Specific Neck Pain: A Population-Based Cross-Sectional Descriptive Study. *Pain Med* 17: 2369-2377.
6. Gerwin RD (2001) Classification, epidemiology, and natural history of myofascial pain syndrome. *Curr Pain Headache Rep* 5: 412-420.
7. Domingo T, Blasi J, Casals M (2011) Is interfascial injection with ultrasound guided puncture useful in treatment of myofascial pain of the trapezius muscle? *Clin J Pain* 27: 297-303.
8. Jaeger B (2013) Myofascial trigger point pain. *Alpha Omegan* 106: 14-22.
9. Benjamin M (2009) The fascia of the limbs and back a review. *J Anat* 214: 1-18.
10. Hong CZ (2006) Treatment of myofascial pain syndrome. *Curr Pain Headache Rep* 10: 345-349.
11. Won-Sik B, Hyun-ok Lee, Jae-Wook S, Keon-CHeo L (2016) The effect of middle and lower trapezius strength exercises and levator scapulae and upper trapezius stretching exercises in upper crossed syndrome. *J Phys Ther Sci* 28: 1636-1639.
12. Pasqualucci A, Varrassi G, Braschi A, Peduto VA, Brunelli A, et al. (2007) Epidural local anesthetic plus corticosteroid for the treatment of cervical brachial radicular pain: Single injection versus continuous infusion. *Clin J Pain* 23: 551-557.
13. Ustun N, Arslan F, Mansuroglu A, Inanoglu D, Yagiz AE, et al. (2014) Efficacy of EMLA cream phonophoresis comparison with ultrasound therapy on myofascial pain syndrome of the trapezius: a single-blind, randomized clinical study. *Rheumatol Int* 34: 453-457.