

ASSOCIATED INJURIES AND COMPLICATIONS IN FLOATING KNEE MANAGEMENT

HANS-MOEVI AKUE A., LAWSON E., GOUKODADJA O., OUEDRAOGO A.

Department of Orthopaedic and Traumatology Surgery
Cotonou Teaching Hospital, Benin

Correspondence to: Dr. Lawson Eric, 03BP: 641 Jericho Cotonou, Republic of Bénin. Email: ericson_bj@yahoo.fr

ABSTRACT

Objective: This retrospective study set out to explore associated injuries and complications in floating knee management.

Materials and Method: The investigation lasted ten years from 1st January, 2000 to 31st December, 2009. All the patients admitted in that period with a floating knee were included. Fifty two files with a floating knee were included with 53 floating knees. One of them had a bilateral floating knee. The floating knees were classified according to Fraser's classification.

Results: The average age was 38.37 years with extremes of 18 and 81 years. There were 40 men and 12 women that is a sex-ratio of 3.33. There were polytrauma context in 24 cases. Ninety seven associated injuries (22 head injury, 6 upper limb fractures, 2 pelvic ring trauma, 2 cervical trauma, 17 knee hemarthrosis, 2 paralysis of fibular nerve associated to a displaced fracture of neck of fibula, 45 cases of open skin injury). Twenty five patients had received orthopaedic treatment. The complications were as follows: 8 knee stiffness, 7 vicious callus, 1 aseptic pseudarthrosis, 2 osseous infection. Twenty seven patients with a total of 28 floating knee had been treated surgically. Nine (33.33%) of them had presented at least one complication. We noted 4 knee stiffness, 3 vicious callus, 2 septic pseudarthrosis, 2 aseptic pseudarthrosis which one occurred on a broken plate, 1 osseous infection and 2 migrations of femoral nail. The afterings at middle follow-up were 2 shortness.

Conclusion: Associated injuries and complications of floating knee are frequent in our activities. Based upon findings, the study suggests that a good outcome of floating knee management will depend on early evaluation and treatment of associated injuries.

Keywords: Associated injuries, complications, Floating knee, Management

INTRODUCTION

Floating knee refers to ipsilateral fractures of femur and tibia. Road accidents with high-energy trauma are the most frequent aetiology leading to that type of injury. In the management of floating knee, the lower limb deformation can hide other associated injuries. Early, secondary or late complications are often frequent.

Through this retrospective study, we intend to identify the associated injuries and complications based on our experience in the management of floating knee.

MATERIALS AND METHODS

This study covered a decade from 1st January, 2000 to 31st December, 2009. It was a retrospective study about associated injuries and complications in management of traumatic floating knee. All the patients admitted in that period with a floating knee were included. One of them had a bilateral floating knee. The data collected from the medical records included; age, gender, type of accident, involved side, the type of associated injury, the treatment, results and the observed complications.

The floating knees were classified according to Fraser classification (Figure 1) (1) which takes into

account all varieties of floating knee fractures involving articular surfaces around the knee, diaphyseal and metaphyseal fractures. Skin wounds were classified according to Cauchoix and Duparc classification (2).

RESULTS

The mean age was 38.37 years with extremes of 18 and 81 years. There were 40 men and 12 women. Road accidents were responsible for 51 cases including 37 cases of motorcycle-car collision. The left side was involved in 32 cases. According to Fraser classification, there were 36 cases of type I, 8 cases of type IIA, 5 cases of type IIB and 4 cases of type IIC.

Floating knee was involved in a polytrauma context for 24 patients. There were 22 cases of head injury, 6 upper limb fractures (3 clavicle fractures, 2 distal radius fractures, 1 forearm fracture), 2 cases of pelvic ring trauma, 2 cases of cervical trauma one of which was associated to brachial plexus injury, and 17 cases of knee hemarthrosis, and 17 cases of knee hemarthrosis.

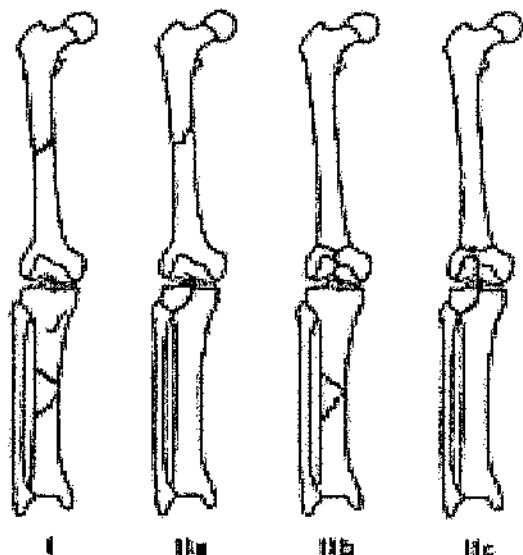
An open injury was noted in 45 cases (84.5%); the tibial bone alone in 22 cases (48.9%), the femur and tibia in 16 cases (35.55%) and the femur alone in 7

cases (15.55%). According to Cauchoix and Dupare classification, there were type I 11 cases (18.03%), type II 30 cases (49.18%) and type III 20 cases (32.79%). Moreover, 2 cases of fibular nerve paralysis were recorded and were associated with a displaced fibular neck fracture. In one of the cases, acute compartment syndrome of the leg occurred.

Orthopaedic treatment was carried out in 25 cases. There were 18 complications. These were as follows; 8 knee stiffness, 7 vicious callus, 1 aseptic pseudarthrosis, 2 osseous infection. Surgical treatment was used for 27 patients with a total of 28 injuries (Table 1). With regard to the femoral bone, 14 cases involved intramedullary fixation by Kuntscher nail while 14 cases involved extramedullary fixation with condylar plate and femoral plate. With regard to tibia bone, 11 cases involved intramedullary fixation by Kuntscher nail and 4 cases involved extramedullary fixation by plate. An external fixator had been used in 3 cases.

Nine (33.33%) of 27 patients who had been treated surgically presented at least one complication. There were 14 complications that is an average of 1.76 complications for each patient. The following were recorded; 4 knee stiffness, 3 vicious callus, 2 septic pseudarthrosis, 2 aseptic pseudarthrosis which one occurred on a broken plate, 1 osseous infection and 2 migrations of femoral nail. The afterings at middle follow-up were 2 shortness. One occurred in a patient who presented a femoral and tibial septic pseudarthrosis and the other in a patient receiving orthopaedic management of leg fracture.

Figure 1



Type I: both fractures involve the shaft without articular involvement of the knee.
 Type II: articular involvement of the knee
 Type IIa: tibia fractures
 Type IIb: intercondylar fractures (T or Y fractures) of

the inferior extremity of the femur

Type IIc: both sites are articular

Table 1

Type of surgical management	Number
Femoral nail	14
Femoral plate/ Femoral condylar plate	14
Tibia nail	11
Tibia screw plate	4
Tibia external fixator	3

DISCUSSION

Floating knee is due to high-energy trauma which often affects other parts of the body (head, chest, abdomen). Twenty four cases of polytraumatism have been found in our study. Zrig *et al.*(3) and Shiedts *et al.* (4) have reported respectively 59% and 100% of polytraumatism. We registered no death. However, other studies have reported a mortality rate from 5.6% to 15% (3, 5, 6, 7).

The association with head injury is relatively frequent according to Rethnam *et al.* (8) with 3 cases in 29 patients, and Pietu *et al.*(9) with 37.8%. There is a high risk of pulmonary complications in case of cerebral injuries. This risk is reduced if the surgical treatment occurred within the 24 hours in patients with head injury (10). If there is a fluctuating conscious level, the right attitude must be to do a computer scan of the brain. If an intracranial haematoma is diagnosed, neurosurgery management is required before the stabilization of fractures.

Studies by Behrman *et al.* (11) and Riska *et al.* (12) reported that pulmonary complications (fat embolism, pneumonia and Adult Respiratory Distress Syndrome) rate is reduced in case of early surgical stabilization of both fractures. In front of floating knee which is due to high-energy trauma, systematical abdominal clinical assessment is required. If abdominal injury is suspected, an echography or better an abdominal scan is indicated.

Few studies in literature mention associated injuries. We registered 6 upper limb fractures (3 clavicles fractures, 2 distal radius fractures, 1 forearm fracture). Rethnam *et al.* (8) found 5 upper limb fractures (4 humerus fractures and 1 forearm fracture) in 29 patients in a study on impact of associated injuries in floating knee. Pietu *et al.* (9) in a retrospective multicentric study found 68% of associated fractures of other limbs. The pelvic ring injuries is infrequent. Indeed, Elmrini *et al.* (13), Zrig *et al.* (3) have respectively found 1 case of acetabulum fracture in 18 floating knees and 2 cases in 39 floating knees.

An articular knee swelling must lead to search ligaments injuries. The literature reports several

studies on the association of ligaments injuries of knee (5,14,15). A good outcome after treatment of the floating knee is associated to appropriate management of the knee ligament injury. Szalay *et al* (15) reports a rate of 53% of knee ligaments injuries.

A predominance of open fractures was found in our study. Other studies have reported 60% to 90% of open fractures (6,7, 9,13,16). This shows the severity of trauma and, in our study, most of the cases were type II and III open injuries according to Cauchoix and Duparc Classification. We did not register any vascular complication. A careful evaluation of peripheral vascular pulses (palpation or hand held Doppler) must be done to suspect an arterial injury. In this case and in absence of critical ischemia of the limb, an angiogram is recommended. Our study concurred with Rethnam *et al.* (8) that repair of the vascular injury is best done after surgical stabilization of the fractures as the floating knee is an unstable injury and manipulation of the fracture after repair of a vessel can put stress on the repair leading to failure.

Our study found 10 vicious callus. This complication is also found in others studies (3, 17,18). Knee stiffness are more frequent after orthopaedic treatment. Ratliff (19) found that internal fixation of both the fractures gave less knee stiffness.

CONCLUSION

Head injuries, open fractures wound injuries; especially in tibia bone with type 2 and 3 according to Cauchoix and Duparc classification were the most frequent associated injuries of floating knee in our study. Knee stiffness, vicious callus, bone nonunion and osseous infection were the main complications. The prognosis in floating knee depends on early precocious evaluation and appropriate management of associated injuries.

REFERENCES

1. Fraser, R.D., Hunter, G.A. and Wadell, J.P. Ipsilateral fracture of the femur and tibia. *J Bone Joint Surg*. 1978 ; **60** B(4):510-515.
2. Cauchoix, J., Duparc, J. and Boulez, P. Traitement des fractures ouvertes de jambe. *Mém Acad Chir*. 1957; **83**:811-822.
3. Zrig, M., Mnif, H., Hammouda, I., *et al.* étude rétrospective de 39 cas. *Tunisie Orthopédique* 2008 ; **1**(2) : 165-170.
4. Schiedts, D., Mukisi, M., Bouger, D. and Bastaraud, H. Fractures de diaphyses femorales et tibiales homolatérales. *Rev Chir Orthop*. 1996; **82**:535-540.

5. van Raay, J.J., Raaymakers, E.L. and Dupree, H.W. Knee ligament injuries combined with ipsilateral tibial and femoral diaphyseal fractures: the "floating knee". *Arch Orthop Trauma Surg*. 1991; **110**(2):75-77.
6. Dwyer, A.J., Paul, R., Mam, M.K., Kumar, A. and Gosselin, R.A. Floating knee injuries: long-term results of four treatment methods. *Int Orthop*. 2005;**29**(5):314-318.
7. Anastopoulos, G., Assimakopoulos, A., Exarchou, E. and Pantazopoulos, T. Ipsilateral fractures of the femur and tibia. *Injury*: 1992; **23**: 439-441.
8. Rethnam, U., Yesupalan, R.S. and Nair, R. The floating knee: epidemiology, prognostic indicators & outcome following surgical management. *J Trauma Management & Outcomes* 2007 ; **1**(2): 1-8.
9. Piétu, G., Jacquot, F., Féron, J.M., *et les membres du GETRAUM*. Le genou flottant : étude rétrospective de 172 cas. *Revue de Chirurgie Orthopédique*. 2007; **93**: 627-634.
10. Poole, G.V., Miller, J.D., Agnew, S.G. and Griswold, J.A. Lower extremity fracture fixation in head-injured patients. *J Trauma*. 1992; **32**(5):654-659.
11. Behrman, S.W., Fabian, T.C., Kudsk, K.A. and Taylor, J.C. Improved outcome with femur fractures: early vs. delayed fixation. *J Trauma*. 1990; **30**(7):792-797.
12. Riska, E.B. and Myllynen, P. Fat embolism in patients with multiple injuries. *J Trauma*. 1982; **22**(11):891-894.
13. Elmrimi, A., Elibrahimi, A., Agoumi, O., *et al.* Ipsilateral fractures of tibia and femur or floating knee. *Intern Orthop (SICOT)*. 2006; **30**: 325-328.
14. Paul, G.R., Sawka, M.W. and Whitelaw, G.P.: Fractures of the ipsilateral femur and tibia: emphasis on intra-articular and soft tissue injury. *J Orthop Trauma*. 1990; **4**(3):309-314.
15. Szalay, M.J., Hosking, O.R. and Annear, P. Injury of the knee ligament associated with ipsilateral femoral and tibial shaft fractures. *Injury*. 1990; **21**(6):398-400.
16. Agoh, S., Bé J., Ouédé, R., Dogba, E., Adibo, G. and Tuo, N. Le genou flottant : à propos de 55 cas traités au CHU de Cocody à Abidjan. *Tunisie Orthopédique*. 2010; **3**(2) : 160 164.
17. Karlström, G. and Olerud, S. Ipsilateral fracture of the femur and tibia. *J Bone Joint Surg (Am)*. 1977; **59**: 240-243.
18. McAndrew, M.P. and Pontarelli, W. The long-term follow-up of ipsilateral tibial and femoral fractures. *Clin Orthop*. 1988; **232**:190-196.
19. Ratliff, A.H. Fractures of the shaft of the femur and tibia in the same limb. *Proc R Soc Med*. 1968; **61**(9):906-908.