

*Full Length Research Paper*

# Prevalence and intensity of nodular oesophagostomosis in West African Long Legged goats in Northern Benin

Sahidou Salifou<sup>1</sup>, Dadjo Florian Daga<sup>2</sup> and Sabbas Attindehou<sup>1\*</sup>

<sup>1</sup>Laboratory of Applied Biology Research, University of Abomey-Calavi, 01 BP 2009 Cotonou, Benin.

<sup>2</sup>Department of Animal Production, Faculty of Agricultural Sciences, University of Abomey, 01 BP 526 Cotonou, Benin.

Accepted 28 January, 2013

**This study was conducted between January and December, 2011 to assess the prevalence and intensity of nodular lesions caused by *Oesophagostomum* species into the intestine of Benin goats. Intestines of 384 West African Long Legged (WALL) goats, from Northern Benin, were examined during slaughter, and 241 intestines (62.8%) were found to be positive for nodular lesions. The infection rate was significantly ( $p < 0.05$ ) higher during the rainy season in comparison with dry season. Animals above one year of ages were mostly affected (82.5%). Extensive lesions were observed in 95 large intestines (24.9%) and calcified nodules were observed in 130 intestines (34%).**

**Key words:** *Oesophagostomum* species, nodules, goats, prevalence, Northern Benin.

## INTRODUCTION

The climatic conditions of tropical Africa are conducive for development of parasites, notably the exogenous stage of their life cycle. Therefore, helminthosis is an absolute and important constraint in livestock production in Tropical Africa. The prevalence of gastrointestinal strongyles and their impact on yields are described by many authors (Sykes, 1994; Mortensen et al., 2003) and several reports are also available regarding haemonchosis, most detrimental of which is strongylosis which is synonymous to small ruminants production in Sub-Saharan Africa (Ouattara and Dorchies, 2001; Achi et al., 2003; Osakwe and Anyigor, 2007; Attindehou et al., 2012). However, information is available regarding other pathogens like *Oesophagostomum*, which also causes important economic losses (Olivares et al., 2001) by decreasing animal productivity and market value of the viscera due to the presence of nodules in the intestines. The assessment of nodular oesophagostomosis importance in Benin is very timely and relevant, especially

in the Northern region where farming is a major activity. This study aimed to determine the prevalence and intensity of nodules due to *Oesophagostomum* spp. in West African Long legged Goats in Benin.

## MATERIALS AND METHODS

### Period and study area

The study was undertaken between January and December, 2011 in the region located between latitudes 9.5° and 12.5° North and longitudes 1° and 4° West, covering four agro-ecological zones of Northern Benin. During the study period, rainfall was 921.5 mm and temperature varied between 16.2 and 40.6°C. Wet season was from May to November.

### Animal

A total of 384 West African Long-Legged (WALL) goats (196 female and 188 males) were selected randomly for the study. On average, 30 animals were screened each month.

### Parasitological examination

The parasitological examination consisting of usual slaughterhouse

\*Corresponding author. E-mail: [sabbastino@yahoo.fr](mailto:sabbastino@yahoo.fr).

**Table 1.** Prevalence of nodular oesophagostomosis relative to the seasons and the animal's age and sex.

Variable	Category	Number of examined animals	Number of infected animals	Infection rate (%)	p value
Season*	Dry	159	91	57.2	0.020
	Wet	225	150	66.7	
Age*	Below one year	144	49	34.0	0.000
	Above one year	240	192	80.0	
Sex	Female	193	123	63.7	0.278
	Male	191	118	61.8	
Total	-	384	241	62.8	

\*Significant variation factor.

inspection has been used to assess the prevalence and the intensity of nodular lesions in animals. After slaughter, the intestines were isolated, emptied and washed with pressured tap water injection. The external and internal mucosa of both intestines was inspected carefully in search of nodules. Some nodules were incised with a knife in order to characterize the nature (calcified or not calcified). Nodular lesions affecting more than 50% of the length of the small intestine or large intestine were called generalized and considered as a result of heavy infection. When nodules affect less than 25% of the tract, the infection was declared localized. The other cases are referred to as fairly extensive lesions. A logistic regression was performed in Stata 11 (Nicoletti, 2011) to analyze and evaluate age, sex and season influence upon the prevalence and intensity of nodular lesions.

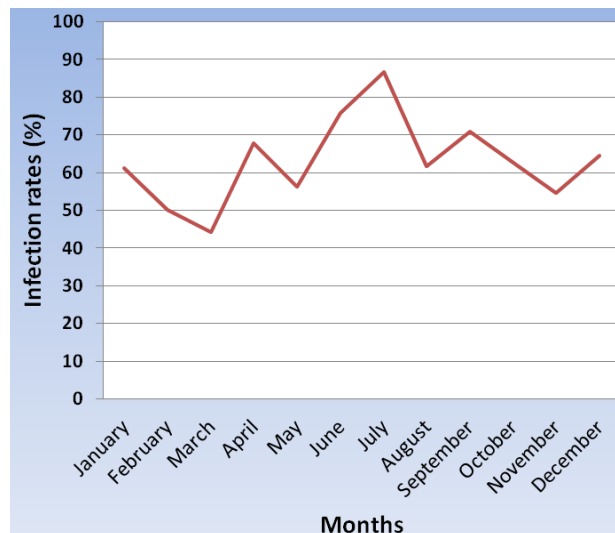**RESULTS**

**Prevalence of nodular oesophagostomosis and variation factors**

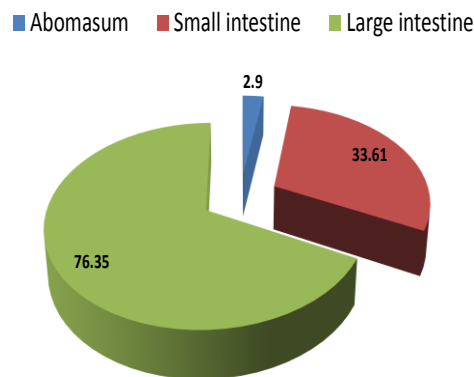
Out of 384 examined animals, 241 (62.8%) were positive to nodular oesophagostomosis. Figure 1 shows the infection rates recorded monthly. It highlights the endemic nature of the parasitosis whereas Table 1 clearly shows a higher prevalence in the wet season ( $p < 0.05$ ). Animals aged one and older were significantly ( $p < 0.001$ ) more infested than younger ones. No influence of the animal sex could be proven.

**Location and intensity of nodular lesions**

Parasitic nodules due to *Oesophagostomum* spp. were found on the terminal portion of the abomasum, on the small intestine and on the large intestine. The mucosa of the large intestine was the most dominant location of nodules (Figure 2). Respectively, 17.8, 25.7, and 56.4% of infected viscera had generalized, fairly extensive and localized lesions.



**Figure 1.** Nodular oesophagostomosis prevalence.



**Figure 2.** Nodular lesions localisation (Frequency of infection; %).

## DISCUSSION

The prevalence of nodular oesophagostomosis was important (almost 63%) even if lower values have been recorded in neighboring regions. This is the case in Northern Nigeria where Nwosu et al. (2011) reported a prevalence of 71% in a slaughterhouse investigation. This difference is probably due to the fact that slaughterhouses surveys are likely to overestimate pathology's prevalence. Indeed, the candidates for the slaughter often look bad, health wise. However, it is clear that oesophagostomosis is an important strongylosis in West African Long Legged goats in West Africa.

*O. columbianum* have been reported in 88.3% of goats in the Central Plateau of Burkina (Belem et al., 2005). The nodular oesophagostomosis was reported in 62% of goats in the Middle Guinea by Barry et al. (2002). Contrary to this, a low rate of 43% was reported by Achi et al. (2003) in savannah region in north of Ivory Coast. The results of the study revealed a fairly clear seasonal variation, with high levels of infection during wet, which was consistent with the observations of Nwosu et al. (2011) but somewhat contradicted the results recorded in Burkina Faso and Ivory Coast (Belem et al., 2005; Achi et al., 2003). A highly significant effect of the age was observed. The elderly were most affected. This is understandable considering the chronicity of nodules, especially in the calcification phase. The intensity of the lesions has been similar to reported findings (Kulo and Seme, 2007; Nwosu et al., 2011).

## Conclusion

Nodular oesophagostomosis must be considered as the second main strongyle of high sanitary importance for livestock in Northern Benin after *Haemonchus contortus*. The control of this *Oesophagostomum* spp is very necessary and need to be conducted based on climatic calendar, in association with haemonchosis management.

## ACKNOWLEDGEMENTS

The study was funded by Association Doguici NGO through its West African Zoopole Program and with the support of Benin Ministry of High Education and Scientific Research. The authors express their gratitude to these partners.

## REFERENCES

- Attindéhou S, Salifou S, Biaoou CF, Gbati OB, Adamou-N'diaye M, Pangui LJ (2012). Epidemiology of haemonchosis in sheep and goats in Benin. *J. Parasitol. Vector Biol.* 4(2):20-24.
- Osakwe II, Anyigor SI (2007). Prevalence of gastrointestinal helminths in West African Dwarf (WAD) goats in an agrarian agro-ecosystem. *Anim. Res. Int.* 4(3):728-732.
- Belem AMG, Kaboré A, Bessin R (2005). Variations saisonnières des helminthes gastro-intestinaux chez la chèvre du plateau central du Burkina Faso. *Rev. Elev. Med. Vet. Pays Trop.* 58(1-2):37-43.
- Ouattara L, Dorchie PH (2001). Helminthes gastro-intestinaux des moutons et chèvres en zones sub-humide et sahélienne du Burkina Faso. *Rev. Méd. Vét.* 152(2):165-170.
- Nicoletti NP (2011). Introduction to stata 11 - Getting started with stata programming. University at Buffalo (Sunny), Department of Political Science. p 56.
- Barry AM, Pandey VS, Bah S, Dorny P (2002). Etude épidémiologique des helminthes gastro-intestinaux des caprins en Moyenne Guinée. *Rev. Elev. Méd. Vét. Pays Trop.* 55(2):99-104.
- Achi YL, Zinsstag J, Yèo N, Dea V, Dorchie PH (2003). Épidémiologie des helminthoses des moutons et des chèvres dans la région des savanes du Nord de la Côte d'Ivoire. *Rev. Méd. Vét.* 154(3):179-188.
- Sykes AR (1994). Parasitism and production in farm animals. *Anim. Prod.* 59:155-172.
- Mortensen LL, Williamson LH, Terrill TH, Kircher R, Larsen M, Kaplan RM (2003). Evaluation of prevalence and clinical implications of anthelmintic resistance in gastro-intestinal nematodes of goats. *J. Am. Vet. Med. Assoc.* 223(4):495-500.